Multiple Oral Squamous Cell Carcinoma in a patient with a history of chemical warfare

Abstract:
Introduction:
Oral squamous cell carcinoma usually occurs primary and lonely. Multifocal is considered a rare complication. Various factors have been reported in the literature as contributing to the multiplicity of oral squamous cell carcinoma (OSCC) lesions. It is also possible that chemical warfare agents, due to their cumulative effects, may play a role in the development of multiple lesions.
Case report: A 60-year-old male patient with history of chemical warfare and the chief complaint of a painful ulcer in his mouth from the past two months referred to us at Shahid Beheshti Medical University. Intra-oral examination revealed multifocal White non removable non-homogenies plaque lesion on the left pterygomandibular, left maxillary mucosa and on the anterior mandibular ridge. Incisional biopsy of lesions was performed from all sections. The final diagnosis was early invasive squamous cell carcinoma.
Conclusion:
In patients with head and neck cancer, particularly squamous cell carcinoma (SCC), in addition to risk assessment, inquiring about a history of participation in war may also be helpful.
Key word: Oral squamous cell carcinoma, Multifocal Oral SCC, Head and Neck Cancer, chemical warfare, Sulfur Mustard.

1. Introduction

OSCC is one of the most common head and neck cancers, which has increased in the younger age group in many countries in recent decades [١]. The wide range of occurrence of oral cancers cannot be attributed to only one cause because it is usually the result of several etiological factors that act over time. About 75% of all oral cancers are caused by tobacco and alcohol consumption in any form. Another important etiological factor is oral potentially malignant disorders (OPMDs), which are characterized by an increased chance of turning into malignancy, and their progression to malignancy is only a potential risk because any type of disorder cannot always turn into a malignant condition [٢]. These lesions include more than twenties entities like Leukoplakia, Erythroplakia, Erythroleukoplakia, Oral Lichen Planus, Oral Submucous Fibrosis and oral dysplasia that are lesions with different clinical appearance, histological subtypes and risk factors/etiologies and comprise various entities [٣]. Exposure to carcinogenic and toxic substances and chemical warfare agents, can also play a role in the development of oral SCC[٤].

The incidence of Multiple Oral Squamous Cell carcinoma was less than 10%. The etiological factor Remain unclear, But In some studies ,Its main causes were chewing betel quid and oral submucous fibrosis [5]. In the other study, multiple oral squamous cell carcinoma was reported after allogeneic stem cell transplantation complicated with chronic graft-versus-host disease [6].
Warfare often involves the use of chemical agents, either as weapons (e.g., mustard gas, Agent Orange) or through the destruction of industrial infrastructure, which can release carcinogenic substances into the environment. Prolonged or high-level exposure to such toxic chemicals has been linked to an increased risk of various cancers.
One important group of chemicals used in war is alkylating agents, like sulfur mustard, which are known to damage DNA. Studies have shown that individuals exposed to sulfur mustard during wars (e.g., the Iran-Iraq war) had significantly higher risks of developing cancers [7]. Oral cancer, particularly squamous cell carcinoma, may be associated with such exposures due to the inhalation or ingestion of carcinogens, which come into direct contact with the oral mucosa. Inflammatory responses and DNA mutations caused by these chemicals may lead to malignant transformation over time[8].
The aim of this study is report an unusual and multiple Oral Squamous Cell Carcinoma in a patient with a history of chemical warfare.

2. Case report

A 60-year-old male patient referred to the Department of Oral Medicine Shahid Beheshti University,

In Press

Tehran, Iran with the chief complaint of painful ulcer in his mouth from past two months. The patient was a heavy smoker and usually smoked at least one packet a day since the last 40 years. The item listed in the patient's medical history are hypertension & lung disease due to chemical warfare. Medication was taken by the patient include Losartan, Aspirin, Salbutamol Inhaler, Salmeterol Inhaler and Clobetasol.

The lesions growth were sudden onset and increased to present size within a two month duration. The patient had used the oral suspension Nystatin for many years without any result before visiting our department, and two weeks before coming to us he used AAFTIN Gel (contain of Liquorice root extract) on the lesions that made the lesions feel worse.Extra-oral examination revealed bilateral, palpable, multiple, firm, mobile and tender submandibular lymph nodes, whereas intra-oral examination revealed: first area, White non removable non-homogenies plaque lesion on the left pterygomandibular and buccal mucosa that extended to the left labial mucosa and left maxillary mucosa , ridge and vestibule .the second area ,an exophytic lesion with verrucous surface in the left retromalarpad that in some part ulcers was observed with 3*4 cm and firm consistency(Fig 1). The third area, non-removable non-homogenies plaque with rough and papillary surface on the left maxillary ridge (Fig 1). The fourth area, a white exophytic lesion with verrucous surface on the anterior mandibular ridge with firm consistency (Fig 1).

The panoramic view requested for the patient and it was normal in the regions of the lesions and other parts.

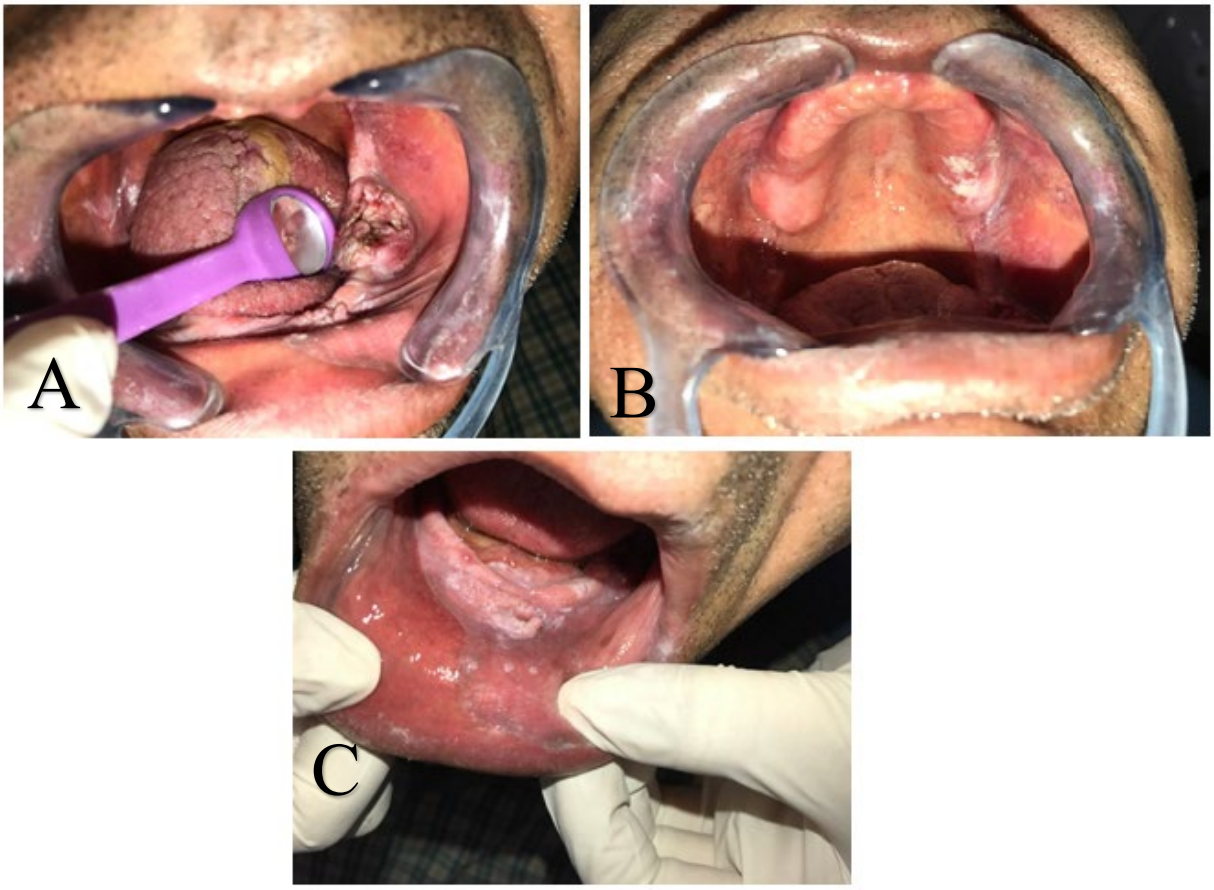

Figure 1: A, An exophytic lesion with verrucous surface in the left retromalarpad that in some part ulcers was observed with 3*4 cm and firm consistency.B: Non-removable non-homogenies plaque with rough and papillary surface on the left maxillary ridge. C: A white exophytic lesion with verrucous surface on the anterior mandibular ridge with firm consistency.

Based on clinical and radiographic findings, most probable diagnose was PVL with malignancy changes. Incisional biopsy of lesions was performed. Samples were taken from three parts of the

mouth, Labial mucosa of anterior mandible, Left posterior mandible mucosa and Left posterior maxillary mucosa with size of 1*0.5*0.3 cm, 2.2*0.6*0.4 and 2.3*0.8*0.3 cm, respectively. The samples submitted for histopathological examination.
Sections showed a malignant epithelial lesion covered by heperparakeratinized stratified squamous epithelium with exophytic, endophytic and papillary proliferation and club shaped rete ridges. The epithelium cells showed hyperchromatism, pleomorphism, increased N/C ratio, mitoses, prominent nucleoli and keratin pearl formation. Focally islands of malignant epithelial cells invaded to the superficial connective tissue and micro abscess formation are seen .In underlying connective tissue sever chronic inflammatory cells infiltration was seen. The final diagnosis was compatible with early invasive squamous cell carcinoma (Fig 2).
The patient underwent a complete excision of primary lesions with unilateral neck dissection.
Patient has been treated with chemotherapy and radiotherapy for 30 secessions. After treatment period, the patient had a normal condition for almost a year. In the recent fallow up, the patient had recurrence in retro molar pad region, so chemotherapy treatment was started again and re-surgery was not performed due to the patient's condition.
Unfortunately, the patient died within few days of excisional biopsy.

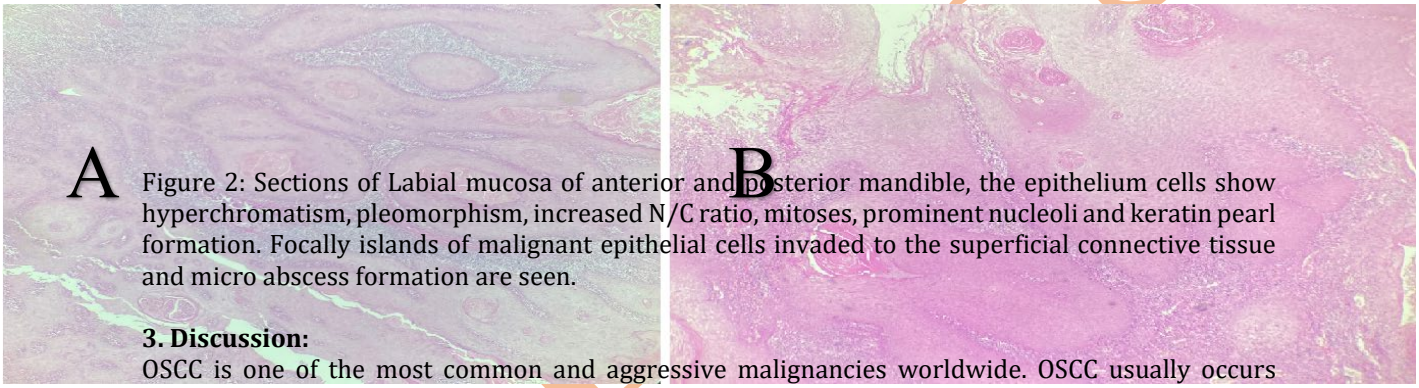

Figure 2: Sections of Labial mucosa of anterior and posterior mandible, the epithelium cells show hyperchromatism, pleomorphism, increased N/C ratio, mitoses, prominent nucleoli and keratin pearl formation. Focally islands of malignant epithelial cells invaded to the superficial connective tissue and micro abscess formation are seen.

3. Discussion:
OSCC is one of the most common and aggressive malignancies worldwide. OSCC usually occurs primary and lonely .Multifocal is considered a rare complication. The etiology of multiple OSCC is unclear [5].
War can increase the incidence of oral cancer for various reasons. One of them is due to the use of carcinogenic substances and toxins, and another is due to the psychological effects that occur after the war and cause the person to consume more cigarettes and alcohol, which is one of the etiologies of oral cancer[9].
It is not possible to say whether multifocal SCC is related to the chemical effect or not but the study of Thomas James has explained that, dermal toxicity was seen as the most appropriate measure for toxicity, however inhalational toxicity must be taken into account when utilising simulants with high volatility/vapour pressure. Oral involvement is possible only when non-principled protocols are used to help the infected person and thus cause the person to be involved through hand-to-mouth transfer or spread to more sensitive areas of the body such as the face, eyes or nose. Many skin studies are performed by simulants and mouth, but because the risk of accidental consumption of simulants is not easily controlled, any chemical containing the GHS classification indicated in the red category should not be used so there are no reliable results[10].
Various chemicals have been used as weapons in wars, one of the most important of which was World Wars I and II. Another war in which chemical weapons were used was the Iran-Iraq war. The use of sulfur mustard in this case has been confirmed in numerous articles[\1]. In a study conducted on chemical victims in the Iran-Iraq War, Zafarghandi and colleagues concluded that the sulfur mustard caused an increase in the incidence of cancer[12]. In other studies, SM gas has been mentioned as a cause of mutations and chromosomal aberrations[11].
As previously mentioned, SCC is a multifactorial disease. In this reported case, a multifocal pattern of SCC was observed, which is rare. The atypical presentation seen in this case appears to be due to the cumulative effect of several risk factors. One of the most important risk factors in this case is a history of chemical exposure during the war, which led to severe illnesses. Another risk factor is smoking, which the patient reportedly resorted to heavily due to psychological effects of the war. Based on

these explanations, it seems that a history of chemical exposure may significantly contribute to the increased incidence of oral cancers. It is therefore recommended that future studies investigate the impact of war-related exposures and carcinogenic agents on the prevalence and clinical presentation of oral cancers.

4. Conclusion

OSCC usually occurs primary and lonely, Multifocal is considered a rare complication. This rare form of the disease can be caused by a variety of factors. One possible cause is chemical warfare.

In Press

5. Acknowledgements:
The authors would like to express their gratitude to the staff of the Department of Oral Medicine at Shahid Beheshti University of Medical Sciences for their support in clinical assessment and patient care. We also appreciate the cooperation of the patient and his family in sharing his medical history.

6. Ethical permissions:
This case report was conducted in accordance with the ethical standards of the institutional and national research committee and with the 1964 Helsinki Declaration and its later amendments. Written informed consent was obtained from the patient's legal guardian for publication of this case and accompanying images.

7. Conflicts of interests:
The authors declare that there is no conflict of interest regarding the publication of this paper.

8. Authors contribution:
Hamed Mortazavi conceived the idea for the manuscript, conducted the literature review, and performed the final editing of the paper. Sara Dalirani and Hasan Mir Mohammad Sadeghi were responsible for the clinical supervision and surgical management. Mahsa Ladanmoghaddam coordinated the case report, collected clinical data, and prepared the manuscript draft. All authors reviewed and approved the final manuscript.

9. Funding/Support:
This study received no specific grant from any funding agency in the public, commercial, or not-for-profit sectors.

10.References:

[1] Ng JH, Iyer NG, Tan MH, Edgren G. Changing epidemiology of oral squamous cell carcinoma of the tongue:A global study. Head Neck 2017;39:297-304. doi:10.1002/hed.24589.

[2] Anwar Sana, Tyagi Nutan1, Mathias Yulia L, Javed Danish. A Five Year Retrospective Study of Oral Potentially Malignant Disorders (Opmds) and Oral Squamous Cell Carcinoma (OSCC) and their Associated Risk Factors. J of Datta Meghe Institute of Medical Sciences University 2023;18:460-7. DOI:10.4103/jdmimsu.jdmimsu_94_23.

[3] Akrish S, Eskander-Hashoul L, Rachmiel A, Ben-Izhak O. Clinicopathologic analysis of verrucous hyperplasia,verrucous carcinoma and squamous cell carcinoma as part of the clinicopathologic spectrum of oral proliferative verrucous leukoplakia: A literature review and analysis. Pathol Res Pract 2019; 215:152670. doi:10.1016/j.prp.2019.152670.

[4] Monaghan NP, Duckett KA, Nguyen SA, Newman JG, Kejner AE, Albergotti WG. Agent Orange and head and neck cancer: A systematic review and meta-analysis. World J Otorhinolaryngol Head Neck Surg. 2024; 27:11:138-146. doi: 10.1002/wjo2.198.

[5] Lin X, Wu X, Gomaa A, Chen J, Wu L, Xie X, et al. Analysis of risk factors for multiple primary oral squamous cell carcinoma: a cohort study. Clin Oral Investig. 2020;24:3147-55. doi: 10.1007/s00784-019-03189-0.

[6] Katz J, Saleh W, Alharbi H, Farhadfar N. Multiple oral squamous cell carcinoma 6 years after allogeneic stem cell transplantation complicated with chronic graft-versus-host disease: A case report. SAGE Open Med Case Rep. 2022; 10:2050313X221118203. doi: 10.1177/2050313X221118203.

[7] Poursaleh Z, Harandi AA, Vahedi E, Ghanei M. Treatment for sulfur mustard lung injuries; new therapeutic approaches from acute to chronic phase. Daru. 2012;20:27. doi: 10.1186/2008-2231-20-27.

[8] Razavi SM, Abdollahi M, Salamati P. Cancer Events After Acute or Chronic Exposure to Sulfur Mustard: A Review of the Literature. Int J Prev Med. 2016 May 19; 7:76. doi: 10.4103/2008-7802.182733. PMID: 27280012; PMCID: PMC4882972

[9] Cigic L, Martinovic D, Martinic J, Kovic M, Druzijanic A, Galic I, Tadin A, Lukanovic B, Duzel M, Poklepovic-Pericic T. Increased prevalence of oral potentially malignant lesions among Croatian War invalids, a cross-sectional study. J Clin Exp Dent. 2023; 15:e734-e741. doi: 10.4317/jced.60715.

[10] T.James, S. Collins, and T. Marczylo, Identification of Novel Simulants for Toxic Industrial Chemicals and Chemical Warfare Agents for Human Decontamination Studies: A Systematic Review and Categorisation of Physicochemical Characteristics. Int J Environmental Research and Public Health 2021; 18:8681. https://doi.org/10.3390/ijerph18168681.

In Press

[11] Belal A. Muhammad. Effects of chemical weapons on cancer development in human. KJAR 2016; 1:50-60..doi:10.24017/science.2016.1.1.5
[12] Zafarghandi MR, Soroush MR, Mahmoodi M, Naieni KH, Ardalan A, Dolatyari A, et al. Incidence of cancer in Iranian sulfur mustard exposed veterans: a long-term follow-up cohort study. Cancer Causes Control. 2013;24:99-105. doi: 10.1007/s10552-012-0094-8.

In Press