The role of L-glutamine as therapeutic and protective agent against effect of carbon tetrachloride on the liver of male mice

Abstract

Aims:The study was designed to investigate the role of L-glutamine as therapeutic and protective agent against the effect of carbon tetrachloride on the
liver of male mice.

Materials and Methods: The College of Science/University of Misan animal house raised healthy, adult male 25-30 gm mice at 12-16 weeks. After splitting 50 mice into five groups, 10 male mice were the control and CCl4 the second. Group 3. Fourth (Glutamine, CCl4), fifth. Blood was drawn from chloroform-anesthetized animals and serum stored for biochemical analysis. Control and treated mice' livers were processed for the experiment.

Findings:Normal liver architecture was seen in H&E-stained control mouse liver sections. Although (CCl4) liver sections showed significant histopathological changes, (CCl4 & L-glutamine) showed regeneration, some normal hepatocytes, and inflammatory cells. Near-normal Lglutamine&CCl4 architecture was observed. The central vein had normal polygonal hepatocytes with L-glutamine. PAS-stained liver sections from control mice showed normal fine glycogen granule distribution. Liver sections from (CCl4) group showed mild hepatocyte glycogen reduction and variable PAS staining. Mice liver sections from (CCl4& glutamine) showed histological changes and moderate glycogen granule distribution. Under the microscope, (Glutamine & CCl4) strongly reacted with (PAS), revealing red or pink hepatocyte cytoplasm granules. But L-Glutamine had strong PAS staining and coarse glycogen granule deposition. Group (G2) mice had significantly higher ALT levels ($P<0.001$), while other groups (G3, G4, G5) did not differ significantly from the control group in liver enzyme analysis. G2 and G3 mice had significantly higher AST levels ($P<0.001$), while G4 and G5 did not differ significantly from the control group. The G2,G3,G4 mice group exhibited a significant ALP increase ($P<0.001$). Not significantly different from control G5.

Conclusions:The present study results indicate the protective and therapeutic effects of glutamine, against the CCl4- induced liver injury . The protective efficacy of glutamine was more potent than the therapeutic effect of glutamine, suggesting that pretreatment of glutamine confers liver protection against the toxic agent. Also, the biochemical markers for liver enzymes showed improvement.

Keywords: L-Glutamine,Carbon Tetrachloride(ccl4),Hepatotoxity

In Press

Introduction

The liver is important for the detoxification and metabolism of many compounds in the human body, whether they are endogenous or exogenous. It is considered as the target of many substances processing. Its exposure to toxic chemicals may overwhelm its antioxidant defense mechanism and cause hepatocellular damage . Carbon tetrachloride (CCL4) is a chemical molecule that is toxic and leads to liver damage by generating the free radical trichloromethyl peroxyl radical, which in turn leads to oxidative stress [1]. This hepatocellular injury leads to damage of membrane lipids, enzymes and DNA [2-3]

Amino acids (AAs) are one of the most vital nutrients for human health. Branched-chain amino acids (BCAAs) are a group of three essential amino acids having branched aliphatic side chains: leucine , isoleucine , and valine . BCAAs are involved in energy balance including gluconeogenesis and lipid metabolism and have the potential to ameliorate liver problems, in addition to providing a required substrate for protein synthesis [4]Good nutrition plays a key role in supporting wound healing and tissue regeneration, as the body's need for nutrients, including amino acids, increases under stress conditions, because tissue healing requires cell proliferation. Since some amino acids are involved in the synthesis of collagen, being the most abundant protein in the body, collagen is essential for maintaining the proper structure and strength of connective tissue, such as bones, skin, cartilage, and blood vessels. Therefore, amino acid support is required for collagen biosynthesis. Thus, regulating the availability of amino acids for collagen biosynthesis is crucial for maintaining tissue integrity, as is the case, for example, during wound healing [5-6] On the other hand exposure of tissues to inflammatory or toxic agents leads to increased levels of free radicals. Amino acids support cells againstoxidative damage by forming glutathione, a tripeptide compound (cysteine, glycine, and glutamic acid) found in relatively high concentrations in many body tissues It plays a pivotal role in reducing oxidative stress, maintaining redox balance, promoting metabolic detoxification, and regulating the immune system[7]Glutamine is the most abundant and versatile amino acid in the body, and is of fundamental importance to intermediary metabolism,interorgan nitrogen exchange via ammonia (NH3) transport between tissues, and pH homeostasis.In almost every cell, glutamine can be used as a substrate for nucleotide synthesis (purines, pyrimidines,and amino sugars), nicotinamide adenine dinucleotide phosphate (NADPH), antioxidants, and many other biosynthetic pathways involved in the maintenance of cellular integrity and function[8-9] Studies indicate that glutamine is a key substrate for providing energy to rapidly dividing cells, particularly in intestinal cells and lymphocytes. The glutamine metabolic pathway begins with deaminase action, producing glutamate and ammonia. Further glutamate is converted to ketoacidosis (a-KG), an intermediate product of the tricarboxylic acid (TCA) cycle, which in turn produces ATP. Consequently, glutamine plays a vital role in increasing cell division, modulating immune defenses, and enhancing protein synthesis efficiency, also this suggests that, immunologically, glutamine contributes to suppressing inflammatory signaling and protecting cells against oxidative stress and apoptosis[10-11]. Several studies suggest that glutamine possesses

In Press

anti-inflammatory properties by influencing a number of inflammatory signaling pathways, including nuclear factor κB (NF-κB) and the signal transducer and activator of transcription (STAT) pathways, in the gastrointestinal tract, glutamine contributes to the integrity of intestinal cells by influencing the expression of tight junction proteins.

This is reflected in the maintenance of the intestinal mucosal barrier and the reduction of permeability[12-13]. At the organic level, skeletal muscle is the primary source for the synthesis, storage, and release of glutamine into the bloodstream, while the intestines, liver, kidneys, and immune system are the main sites of its consumption.

Its function in the kidneys is highlighted by its participation in ammonia formation, where its metabolism leads to the production of alpha- ketoglutarate and bicarbonate ions, which supports the regulation of acid-base balance within the body [14].

Materials and methods

Experimental Design and Animal Grouping

The recent study is completed on healthy adult mice,age 12-16 week and the average weight 25-30gm which are breed at the house of animal of the college of Science/University of Misan. The animals are housed under controlled room (12:12) light : dark cycle, they are randomally separated in plastic cages with hygienic bed and were Fed on standard laboratory food, fifty mouse were divided randomly into Five group, each consist of ten mice as follow : **(G1)** untreated group was administered with olive which was used as vehicle, **(G2)** was received only CCl_4 (1ml/kg body weight): olive oil (1:1) in the 1st and 4th day of every week intraperitoneally injected for 4 weeks, (**G3**) was injected with CCL_4 (1ml/kg):olive oil (1:1)in the 1 st and 4 th of every weeks intraperitoneally injected for 4 week and then given drinking water containing glutamine (prepeared by dissolved 4gm of L-glutamine in 1L of drinking water) for 4 weeks. (**G4**) was given drinking water containing Glutamine and then intraperitoneally injected with CCl_4. (**G5**) only given drinking water containg glutamine for 4 week [15-17]

Devices and techniques

Histological instruments and techniques:

Histological techniques Tissue sections were prepared with rotary microtome(Histoline,Italy) and viewed under a light microscope (Takyo,Japan),and photomicrographs were taken with a digital camera

(Canon, Japan) attached to the microscope

Biochemical instruments and techniques:

Biochemical methods included separation of blood serum by centrifuge (Hettich, Germany), accurate weighing of samples and materials by balance (Sartorius, Germany), measurement and adjustment of pH of solutions (Canon, Japan), storage of samples and reagents at required

In Press

temperatures. Serum was also aspirated and transferred by means of micropipettes (Eppendorf, Germany) to other tubes and spectrophotometrically analysed.

Experimental procedure

All animals were anaesthesized with chloroform, and dissected at (30) day after the initiation of the experiment, then blood and liver collected from control and treated group, about (2-3)ml of venous blood was collected from heart directly by puncture with disposable syringes and serum separated, transferred to sterilized tubes and stored at (-20°c) for analysis of liver enzymes (ALT,AST and ALP). The liver from both experimental and control groups were removed and gathered simultaneously during blood collection, 30 day following the start of the study. The liver samples were sliced into appropriate sizes, rinsed with saline solution, and preserved in a 10% formalin solution. The tissues were then prepared for light microscopy as per the procedure outlined by Luna in 1968. Both transverse and longitudinal slices, ranging from 5 to 7 micrometers in thickness, were created and subjected to staining with hematoxylin and eosin (H&E) as well as periodic acid– Schiff (PAS) stains. In the end, the stained samples were analyzed and photographed using a light microscope.

Statistical analysis

Comparison was used to measured the differences among and within the groups (control and treated) for the serum parameters activities. All the results analysed with Analysis of variances (ANOVA) and the means compared with (SPSS) at least significant differences (LSD) on ($P < 0.001$).

Results Histological Study

Liver samples from control mice exhibited hepatic lobules made up of regular, polygonal hepatocytes featuring rounded vesicular nuclei and typical cytoplasm. These hepatocytes assembled into hepatic cord , with liver sinusoids situated between each orderly cord. Some kupffer cells were found dispersed among the sinusoids, and the hepatocytes predominantly had a single nucleus, while some were binucleated and arranged around the central vein. Furthermore, the examination of the liver from control mice revealed portal area containing portal tracts and portal triads, which included a branch of the portal vein, a branch of the hepatic artery, and a branch of the bile duct that was lined with epithelial cells. Additionally, numerous venules and arterioles were identified extending within the sinusoids, positioned between the hepatic plates, and all bile ducts were lined with simple cuboidal epithelium (Fig 1).

Microscopic examination on sections from mice liver subjected to intraperitoneal CCl_4 treatment for 30 days showed marked histopathological changes which comprised, distortion in the typical structure of hepatocytes surrounding the central vein, localized cell death of hepatocytes, deterioration, vacuolated cytoplasm with shrunken nuclei, slight infiltration of immune cells, expanded sinusoids and engorged portal tract, moderate fatty changes, disarray of hepatocytes, gathering of blood and inflammatory cells within the portal tract, thickened

In Press

walls, hyperplasia of the bile duct's epithelial layer, and degeneration of the endothelial layer of the portal vein and its branches which appeared congested, swollen with mild bleeding within the lumen of the vein, while another portal vein exhibited increased wall thickness and separation from adjacent hepatocytes (Fig 2).

Histopathological observations on section of mice liver sections related to (CCL4 and L-Glutamine) group showed regeneration area, the hepatocytes appeared as sheath or plates within liver stroma , some of normal hepatocytes , still there was inflammatory cells , irregular septa , mild congestion of blood vessels, less dilated sinusoids and moderate distribution of kupffer cells, the central vein with normal lining endothelial layer , and mild vacuoles . Normal periportal area, the cellular arrangement around the central vein, mild necrosis, the liver lobules with strains of hepatocytes compared to that with mice liver of (CCL4 group) , the cell boundaries more clear , some hepatocytes was binucleate although the fatty changes was noticed (Fig 3).

Histopathological observations on section of mice liver sections related to (L- Glutamine and CCL4) group showed near normal architecture, normal hepatocytes arranged as cords around normal central vein with normal cells boundaries, some hepatocytes with single nucleus and other binucleate , normal distribution of kupffer cells , less dilated sinusoids , mild infiltrate of inflammatory cells , also some central veins are mild congested (Fig 4).

Histopathological observations on section of mice liver sections related to (L- Glutamine) group showed central vein surrounded by normal polygonal hepatocytes, normal cells boundaries with vesicular nuclei, some of which are mononucleated, while others are binucleate ,hepatic sinusoids appear normal , normal distribution of kupffer cells and hepatic tissue normal with no evidence of any changes

(Fig 5).

The histological observations on liver sections of control mice that stained with (PAS) stain for demonstration the glycogen content showed normal homogenous distribution of fine glycogen granules within hepatocytes cytoplasm, area around the central vein, basement membrane of each cell and the cells boundaries, all the material stained pink and give (PAS) positive results or magenta stain (Fig 6).

Microscopic examination of mice liver sections from CCl_4 group (G2) showed mild reduction in glycogen content within hepatocytes and variable staining with (PAS) referred to reduction in glycogen granules accumulation, number of inflammatory cells also noticed and increased of portal tract walls thickness and mild fatty change (Fig 7).

Findings from microscopic observation on mice liver sections from CCl_4 & glutamine (G3) showed histological alterations and variable degree of glycogen granules content, moderate distribution of glycogen granules , moderate positive reaction with (PAS) and stained granules

(Fig 8) .

In Press

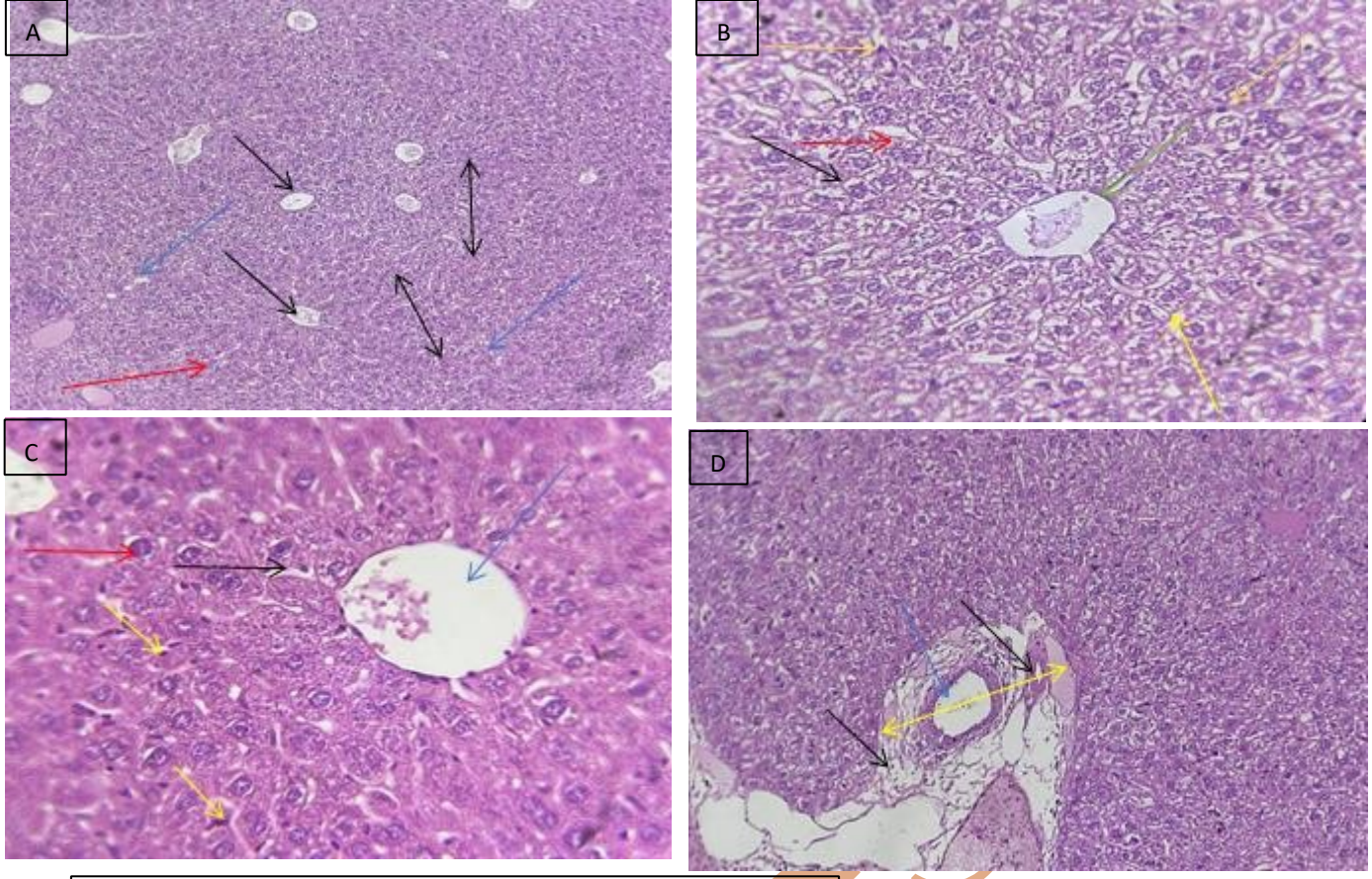

Figure 1 liver histology of the control .H&EStain

Findings from microscopic observation on mice liver sections from glutamine & CCl_4 (G4) showed strong positive reaction with (PAS) indicate to red or pink granules in hepatocytes cytoplasm (Fig 9).

Microscopic examination of mice liver sections from Glutamine group (G5) showed strong positive reaction with (PAS) stain , coarse glycogen granules deposition (Fig 10).

A liver lobules (Black double-headed arrow), each lobule consist of central vein (Single-headed black arrow), hepatocytes arranged as hepatic plates (Red arrow), separated from each other with sinusoids (Blue arrow) . H&E stain (40x).

B hepatic cord (Blue arrow) separated by smaller sinusoids (Red arrow), the hepatocytes (Black arrow) around central vein (Green arrow) , some hepatocyte binucleate (Yellow arrow), and kupffer cells (Orange arrow) was obvious . H&E stain (40x)

C hepatocyte around central vein (Blue arrow), each hepatocyte with single nucleus (Red arrow)
some others binucleate (Orange arrow), normal sinusoids (Black arrow),with kupffer cells (Yellow arrow) , H&E stain (40x)

D the portal area (Yellow arrow) , composed of portal vein (Blue arrow) more connective tissue (Black arrow), hepatic artery (Black arrow) and bile duct , H&E stain (10x) .

In Press

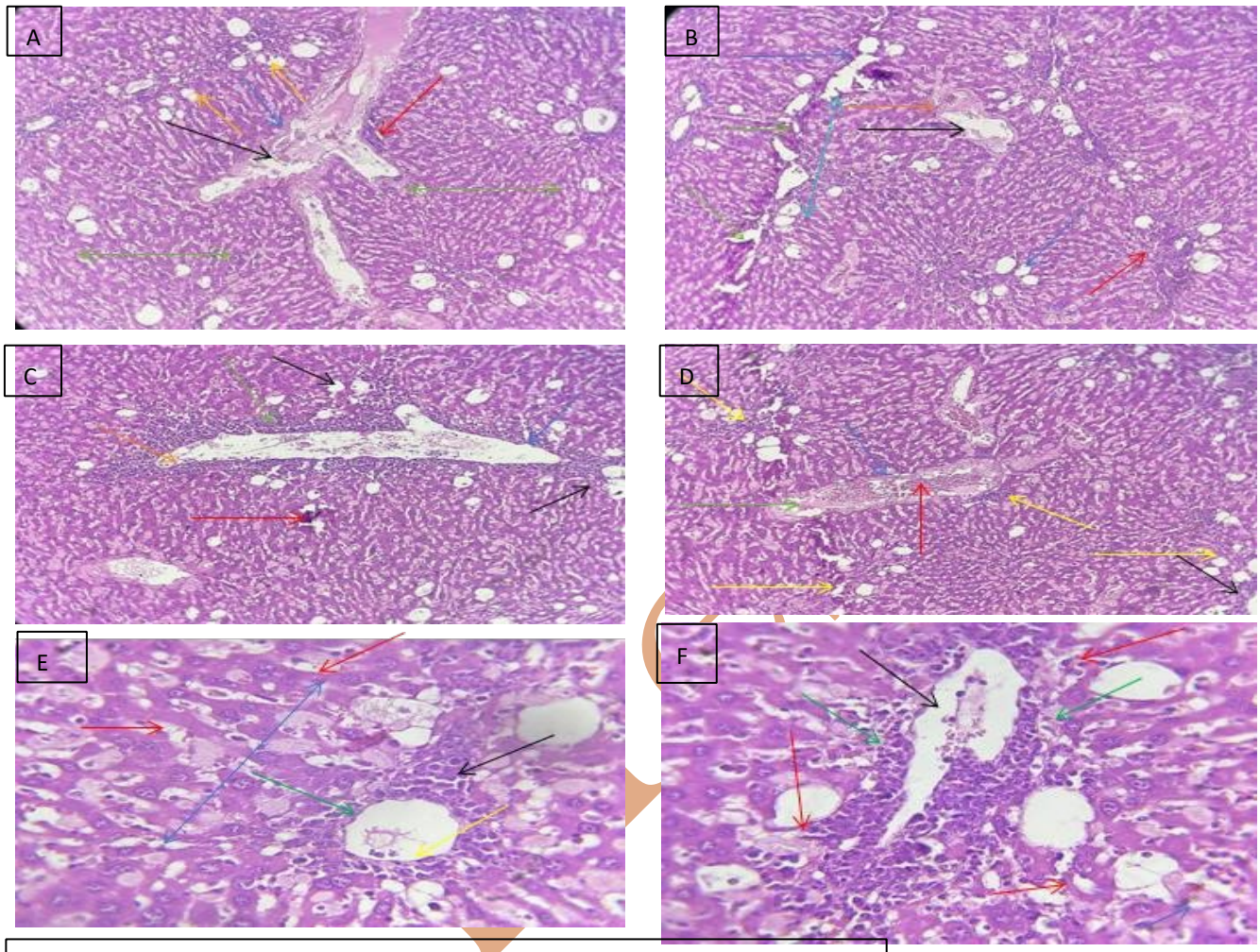

Figure2:Liver histology of the CCl_4-treated group.H&EStain

A destruction and fibrosis (Blue arrow), congested portal tract (Blak arrow), lymphocytic infiltration (Red arrow), disorganized hepatocytes (Green arrow), fatty changes (Orange arrow) and the section revealed to liver steatosis .H&E stain (10x)

B deattached hepatocytes (Green arrow), with moderate fatty change (Blue arrow), congested portal tract (Black arrow) with accumulation of red blood cells (Orange arrow) and infiltration of inflammatory cells (Red arrow) extend through the degenerated hepatocytes (Turquoise arrow) H&E stain (10x)

C dilated portal vein (Blue arrow), hyperplasia of lining epithelial layer (Orange arrow), inflammatory cells (Green arrow), fatty changes like vesicles (Black arrow), and degenerated region (Red arrow)H&E stain (10x).

D congested portal tract (Blue arrow), with accumulation of red blood cells (Red arrow), and inflammatory cells (Green arrow), congested Fig (8) Section in the liver from CCl4 group showed congested portal tract (Blue arrow), with accumulation of red blood cells (Red arrow),

and inflammatory cells (Green arrow), congested sinusoids (Black arrow), and the liver stroma with multiple necrosis foci (Yellow arrow), H&E stain (10x).sinusoids (Black arrow), and the liver stroma with multiple necrosis foci (Yellow arrow), H&E stain (10x)

E distortion of hepatocytes (Blue arrow) around central vein (Green arrow), degeneration of endothelial layer (Yellow arrow), dilated sinusoids (Red arrow),extensive necrosis (Black arrow), H&E stain (40x).

F dilated central vein (Black arrow), surrounded with thrombosis (Green arrow), degeneration of most hepatocytes (Red arrow), and cellular fragments (Blue arrow) H&E stain (40x).

In Press

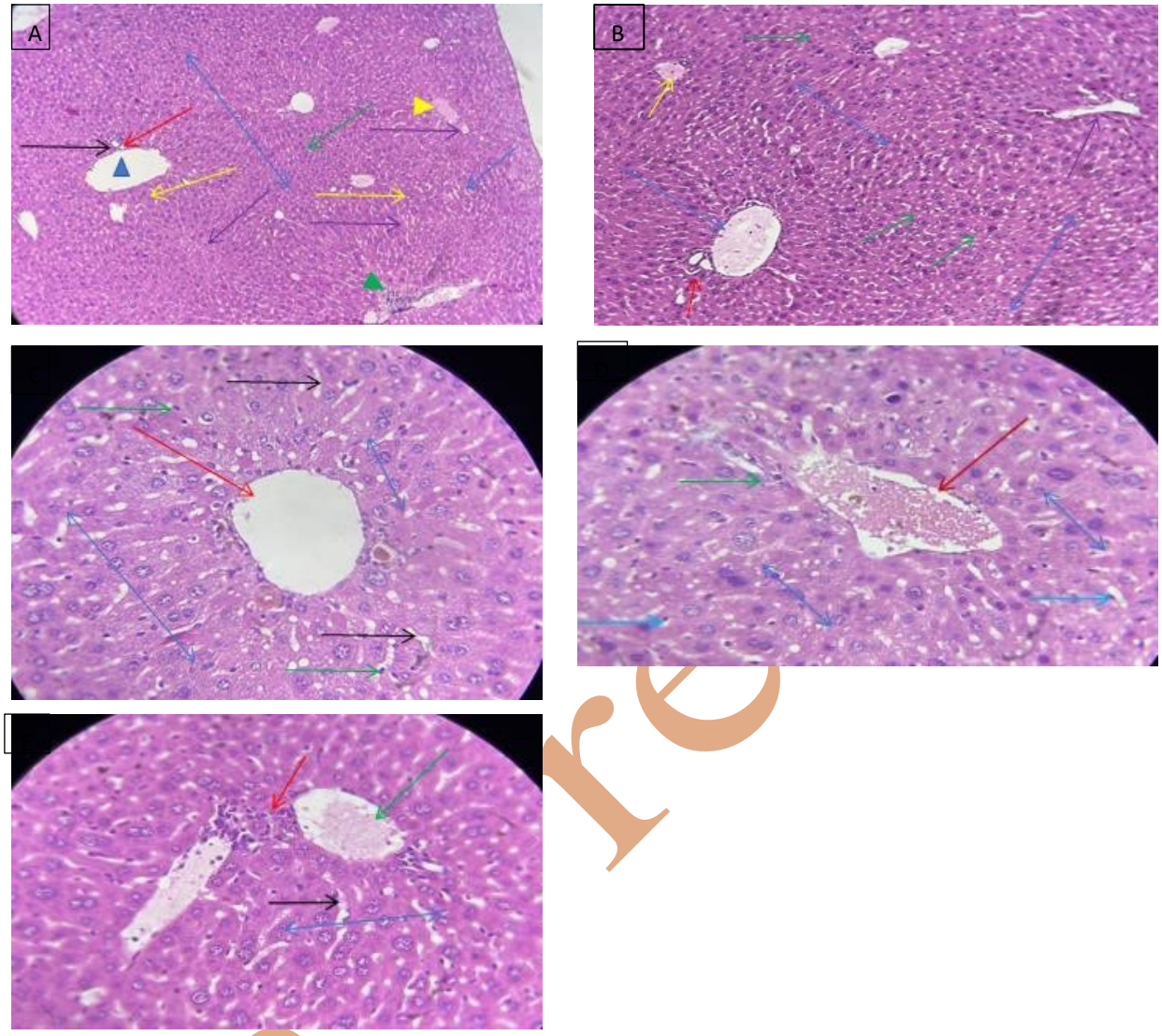

Figure 3: Liver histology of the CCl_4 + glutamine treated group.H&E stain

A showed dilated portal tract (Blue triangles), bile duct (Black arrow), hepatic artery (Red arrow), the regenerative area (Blue double-headed arrow) obvious, other hepatocytes with clear vesicular nuclei (Green arrow), some binucleated (Yellow arrow), less dilated sinusoids (Blue single-headed arrow), mild necrosis (Green arrowhead), mild haemorrhage (Yellow arrowhead), kupffer cells (Purple arrow) H&E stain (10x).

B showed dilated portal tract (Blue arrow), normal blood vessels(Red arrow),mild haemorrhage (Yellow arrow)moderate distribution of kupffer cells (Greenarrow),irregular septa (Purple arrow), and most hepatocytes appeared normal (Blue double-headed arrow) H&E stain (10x).

C showed dilated central vein (Red arrow), normal regenerated hepatocytes (Blue doubleheaded arrow), normal distributed of kupffer cells (Green arrow), less dilated sinusoids (Black arrow), H&E stain (40x).

D showed congested central vein (Red arrow), mild inflammatory cells (Green arrow), normal distributed kupffer cells (Blue single-headed arrow), and most hepatocytes (Blue doubleheaded arrow) appeared normal . H&E stain (40x).

E showed normal hepatocytes arranges as cord (Blue double-headed arrow) around congested central vein (Green arrow), mild inflammatory cells (Red arrow) was obvious , less dilated sinusoids (Black arrow) H&E stain (40x).

In Press

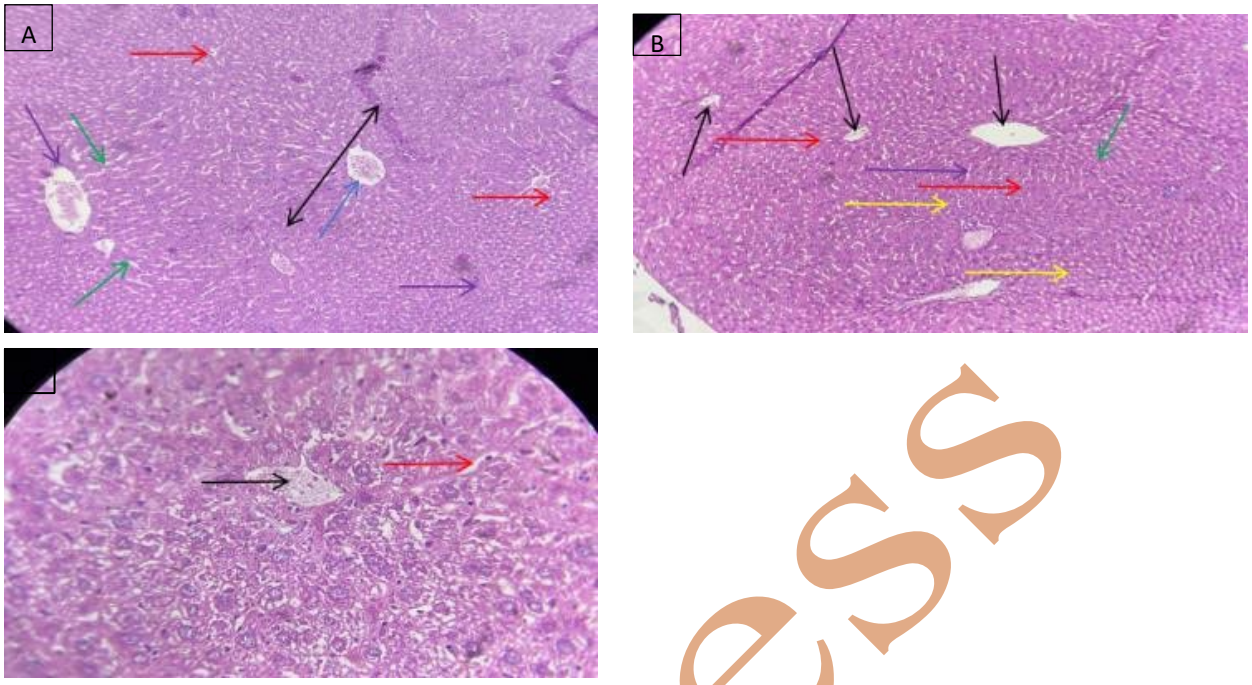

Figure 4: Liver histology of the glutamine + CCl_4 treated group.H&E Stain

A showed normal hepatocytes (Black arrow) arranged as cords around mild congested central vein (Blue arrow), less dilated sinusoids (Green arrow), and kupffer cells (Red arrow), mild inflammatory cells (Purple arrow) H&E stain (10x).

B showed normal central vein (Black arrow) more than one , normal sinusoids (Red arrow), normal distribution of kupffer cell (Yellow arrow), some hepatocytes with single nucleus (Green arrow), other binucleate (Purple arrow), almost normal liver tissue .H&E stain (10x).

C showed mild congested central vein (Black arrow) with normal hepatocytes as cord , less dilated sinusoids (Red arrow) , near normal architecture with normal cells boundaries . H&E

In Press

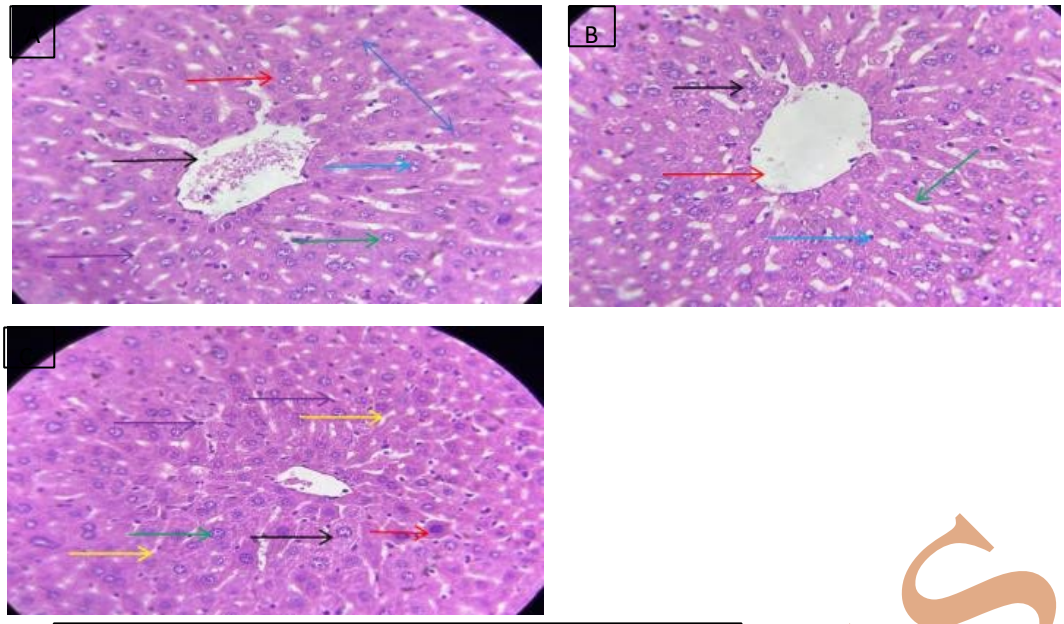

Figure 5: Liver histology of the treated group.H&E Stai

A showed central vein (Black arrow) surrounded by normal hepatocytes (Red arrow) some of which are mononucleated (Green arrow), while others are binucleate (Blue arrow) , arranged in a regular radial pattern (Blue double-headed arrow), hepatic sinusoids appear normal (Purple arrow), also no evidence of pathological changes , indicating normal architecture .H&E stain (40x).

B showed normal hepatocytes (Black arrow) around central vein (Red arrow), normal sinusoids (Green arrow), and kupffer cells (Blue arrow), and hepatic tissue normal with no alteration.H&E stain (40x).

C showed the polygonal hepatocytes (Black arrow), with vesicular nuclei (Green arrow), normal cells boundaries (Red arrow) normal sinusoids (Yellow arrow), kupffer cells (Purple arrow), and hepatic tissue normal with no evidence of any changes .H&E stain (40x).

In Press

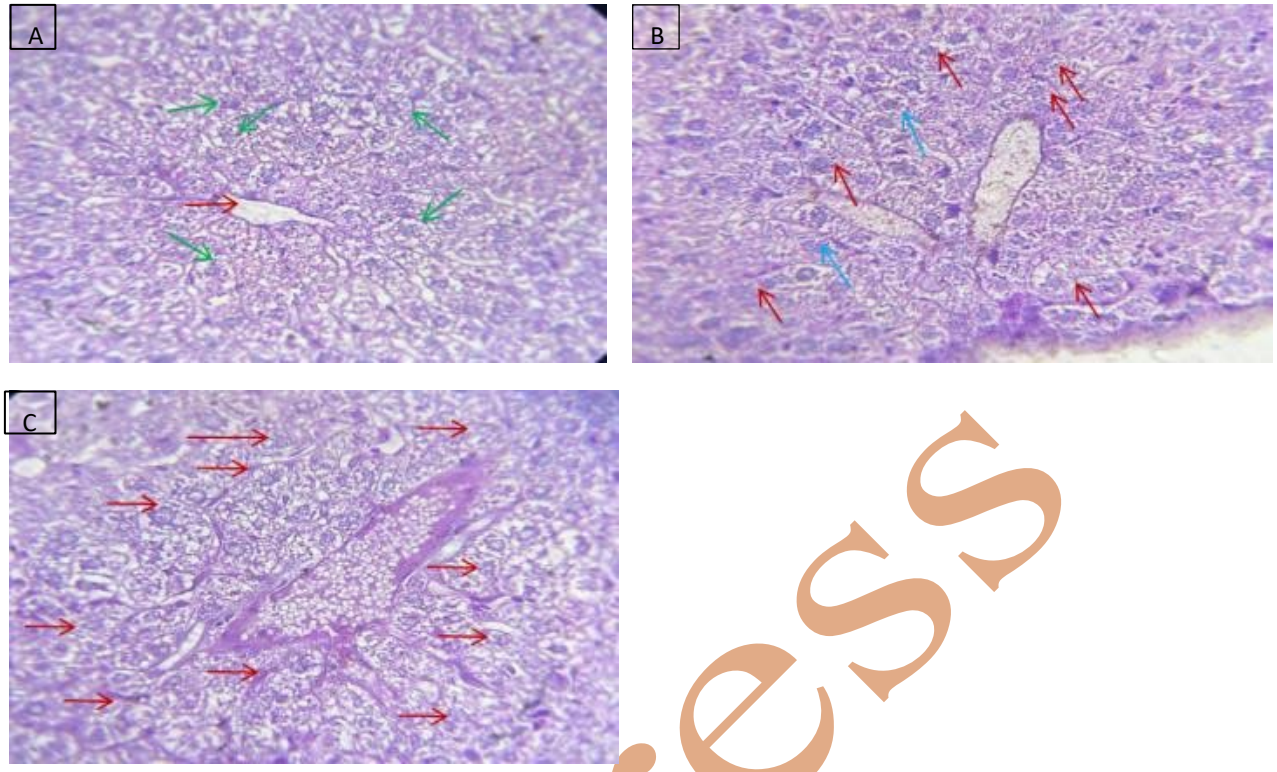

Figure 6: liver histology of the control .PAS Stain

A showing hepatocytes around the central vein (Red arrow) , positive reaction with (PAS) indicated to glycogen granules deposition (Green arrow). PAS stain (40X)

B showing homogenous distribution of glycogen granules (Red arrow), around faint stained nuclei (Blue arrow). PAS stain (40X)

C showing homogeneous distribution of glycogen granules (Red arrow) PAS stain (40X)

In Press

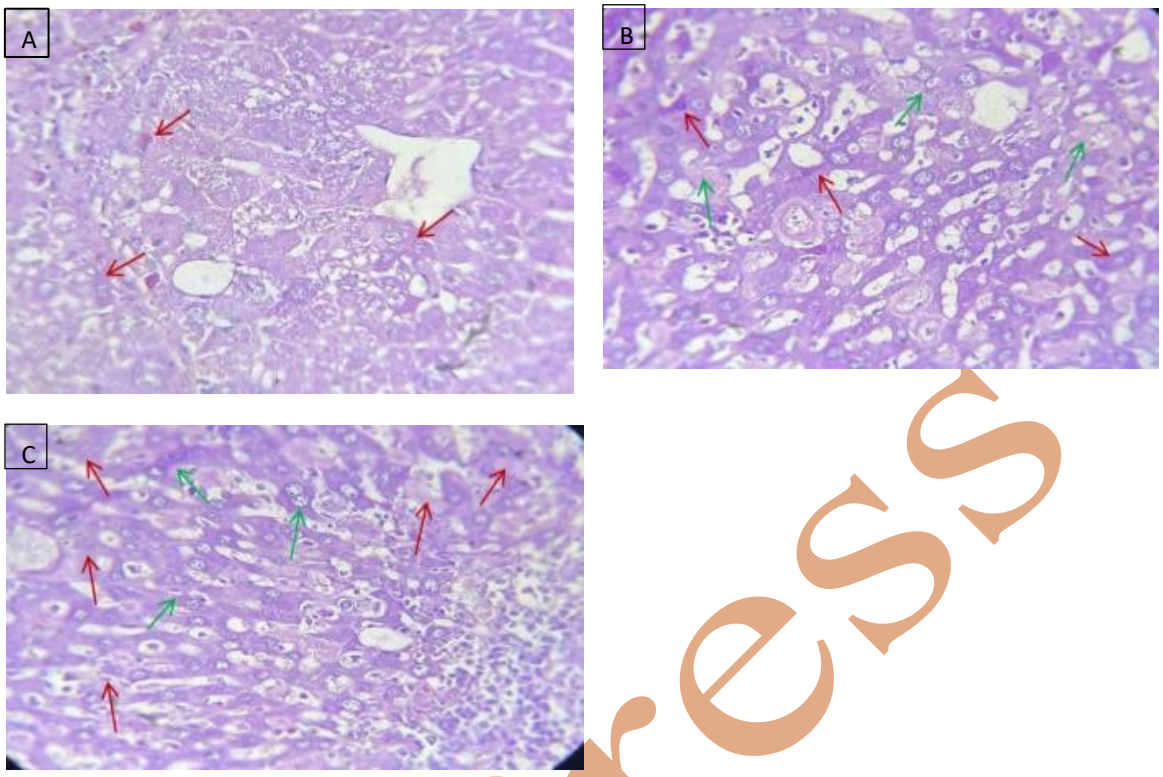

Figure7:Liver histology of the CCl_4 -treated group.PAS Stain

A showing weak reaction with (PAS) stain indicate to mild glycogen content (Red arrow) in liver cells. PAS stain (40X) .

B showing heterogeneous distribution of glycogen granules, mild coarse glycogen granules (Red arrow) in hepatocytes cytoplasm , moderate positive reaction with (PAS) (Green arrow) . PAS stain (40X) .

C showing heterogeneous distribution of glycogen granules, mild coarse glycogen granules (Red arrow) in hepatocytes cytoplasm , moderate positive reaction with (PAS) (Green arrow) . PAS stain (40X)

In Press

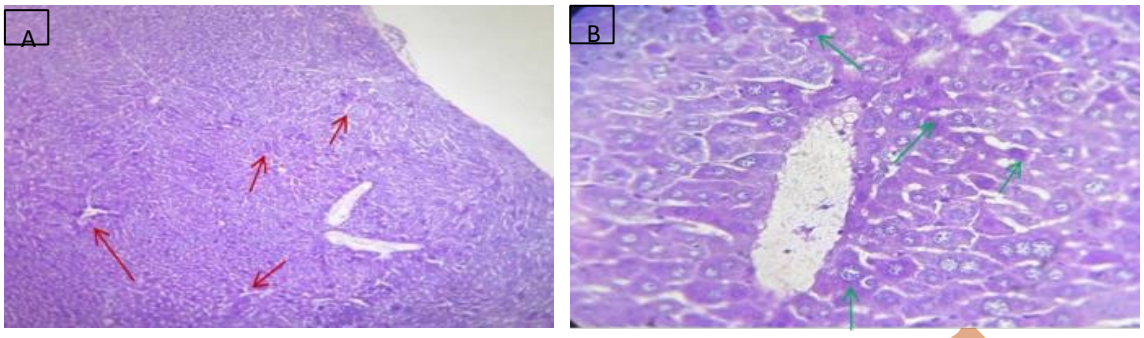

Figure 8:Liver histology of the CCl_4 + glutamine treated group.PAS Stain

A showing moderate distribution of glycogen granules , moderate positive reaction with (PAS) and stained granules (Red arrow) PAS stain (10X) .

B showing moderate distribution of glycogen granules, moderate positive reaction with (PAS) and stained granules (Green arrow) PAS stain (40X) .

In Press

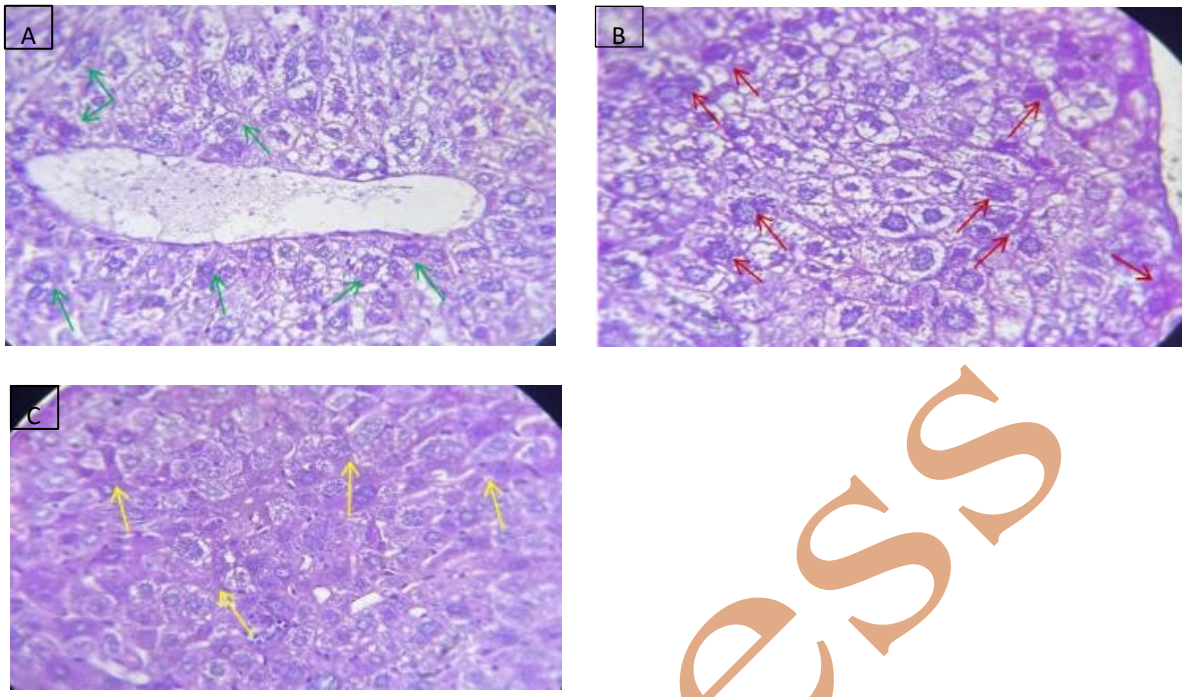

Figure 9:Liver histology of the glutamine + CCl_4 treated group.PAS Stain

A showing strong positive reaction with (PAS) indicate to red or pink granules (Green arrow) in hepatocytes cytoplasm PAS stain (40X) .

B showing strong positive reaction with (PAS) indicate to red or pink granules (Red arrow) in hepatocytes cytoplasm PAS stain (40X) .

C showing strong positive reaction with (PAS) indicate to red or pink granules (Yellow arrow) in hepatocytes cytoplasm. PAS stain (40X) .

In Press

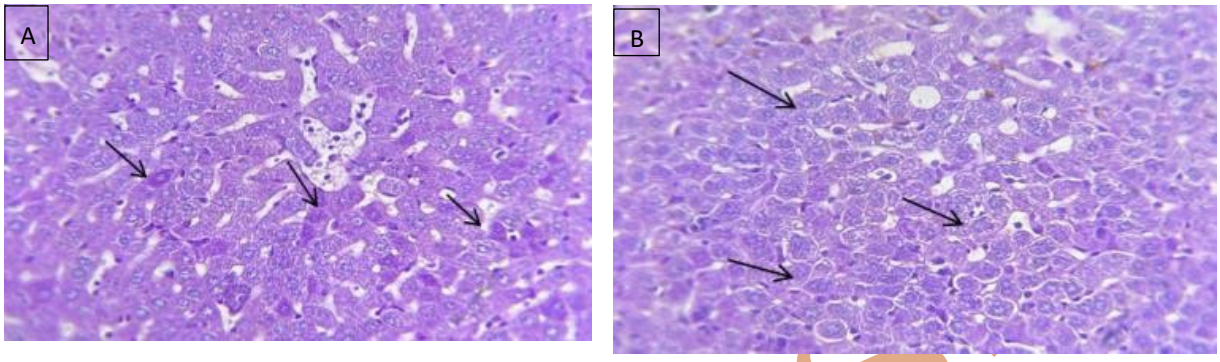

Figure 10:Liver histology of the glutamine-treated group.PAS Stain

A showing strong positive reaction with (PAS) stain , coarse glycogen granules deposition (Black arrow) PAS stain (40X) .

B showing strong positive reaction with (PAS) stain , coarse glycogen granules deposition (Black arrow) PAS stain (40X)

Biochemical Study Results

As shown in the table(3-1)Results of the present study showed significant increase at (P<0.001) in the mean level of serum ALT in mice related to (G2) group, compared to control group that the mean level was, the remaining groups (G3,G4,G5) showed no significant differences compared to control group.Data also showed significant increase at (P<0.001) in the mean level of serum AST in mice related to (G2,G3) group, , compared to control group,the remaining groups (G4,G5) showed no significant differences compared to control group, serum ALP in mice related to (G2,G3,G4) group, , compared to control group,while the group (G5) there was no significant differences was recorded .

In Press

Table (3- 1): Liver enzyme level (ALT , AST , ALP) in the different group , values expressed as(mean ± SD).

Liver Enzymes U/L	Groups	ALT U/L	AST U/L	ALP U/L
	Control (G1)	a 34.130±2.803	220.000±20.747[a]	89.700±6.447[a]
	CCL4 (G2)	353.490±50.005[b]	1308.900±102.224 c	227.700±13.557[d]
	CCL4 & Glutamine (G3)	54.330±6.538[a]	540.360±28.011[b]	135.600±5.739[c]
	Glutamine & CCL4 (G4)	43.000±2.901[a]	239.000±5.403[a]	119.600±7.291[b]
	Glutamine (G5)	32.340±3.210[a]	239.410±20.392[a]	96.000±3.916[a]

The same letter means no significant between treated groups and control group while different letter means there was significant different (P<0.001) between treated group and control group .

Discussion

The liver in the control group shows a normal structure., these resluts similar to[17-19]who describe the normal structure of liver .Liver section of mice CCl_4 group showed obvious changes such as, Itindicates CCl_4 is considered a toxic agent that metabolizes in the .liver damage liver, leading to the production of free radicals and from there to oxidative stress, which is a common pathological mechanism and contributes to the initiation and progression of liver injury. Oxidative stress also begins to produce inflammatory cytokines, causes hepatocyte necrosis and stimulates inflammation, these results agreement with [2021]who report that disturbed liver architecture, inflammatory signs, dilated central vein surrounded with intense cellular infiltration as well as degenerative changes affecting many hepatocytes. Many cells appeared with dense nuclei and acidophilic cytoplasm. The dilated bload vessels observed can be explained by portal hypertension, also the intense cellular infiltration around central vein can be explained by induction of inflammation which is one of mechanisms of CCl_4 induced liver toxicity.

These results also discussed by other workers who stated that liver showed abnormal structure with total absence of normal hepatic lobular architecture. Several nodules of varied diameters were separated by thick fibrous septa . In most locations there was pronounced fatty degeneration of the hepatocytes with scattered necrotic cells. Foci of lobular necrosis with mild inflammation in portal zone and septa were also seen. The liver also showed significant activity and high degrees of fibrosis. The detected liver damage may be related to the metabolism of CCl_4 into a highly

In Press

reactive free radical in the liver. This free radical is metabolized by the P450 enzyme system, forming a highly reactive free radical that initiates lipid peroxidation of cytoplasmic membrane phospholipids. This leads to physiological and morphological changes in liver cells, ultimately causing liver damage[22-23]

Previous reports on effect of CCl_4 showed to alter the retinol pool by impairing CYP4A3 enzymatic activity, which is one of the most significant events that initiates cirrhotic events and upregulation of Tgfb, Timp l and Coll genes, elevated levels of collagen with a concomitant reduction in markers associated with antioxidative processes Also caused by oxidative stress, in addition that CCl_4-induced oxidative stress increased the level of lipid peroxidation as well as production of nitric oxide leading to an enhanced inflammatory response. Here, the reduction of IL-10 reinforces this imbalance and implies a shift toward a strong proinflammatory environment. In a similar manner, ccl4 induces imbalance of hepatic biochemical homeostasis and an immune-mediated injury mediated through up-regulation of pro-inflammatory cytokines, consistent with here bridging oxidative stress with inflammation [24-26]. Another study found that Chronic treatment with CCl_4 leads to hepatocellular damage which in turn activates and induces the proliferation of HSCs fallowed by excessive relcase of ECM. Eventually hepatocytes are replaced by excess ECM that induces scar formation and ultimately Ieads to fibrosis [27]

Experimental CCI_4 poisoning shows that the glycogen loaded hepatocyte is much more resistant to injury than one in which fatty infiltration is present, and glycogen becomes depleted, that is why chronic misusers of alcohol are prone to develop more significant symptoms of CCI_4 induced hepatotoxicity because their liver cells have glycogen depletion and are full[28]

The beneficial effect of L-glutamine in the recent study was proved on mice group (G3) here L-glutamine used as therapeutic agent, The histological features of the control group indicate.Partial improvement in the liver mice, Partially improved Thisattributed to the fact that when glutamine was administered therapeutically after exposure to CCL4, liver damage and cellular oxidation had already occurred. Therefore, the role of glutamine was limited to improving and reducing residual oxidative stress and enhancing cellular repair mechanisms.Our results in agreement with other study reported Shrestha et al[29]the beneficial effect of glutamine against CCl_4 who reported that glutamine administration significantly reduced collagen deposition and alleviated the degree of fibrosis. Glutamine also reduced the expression of cleaved caspase-3 protein, a reliable marker of apoptosis. The percentage of apoptotic Carly cells decreased from 4.7% to 2.7% and 2.3% in the 5 mM and 10 mM glutamine-treated groups, respectively. Glutathione depletion has been observed in various experimental models of liver fibrosis. Since glutamine is the primary precursor to the synthesis of the cellular antioxidant glutathione, treatment capable of restoring depleted glutathione content would reverse the process of fibrosis formation.

Several studies have investigated the therapeutic effect of glutamine against other chemical toxins,study by schemeitt et al.[30] who mentioned the beneficial effect of L-glutamine against thioacetamide in his study, Glutamine reduced lipid peroxidation by 36.36% after 24 hours,

In Press

68.97% after 36 hours, and 30.30% after 48 hours. The decrease in TBARS after glutamine administration was also associated with a reduction in necrosis and inflammation scores.

Another study by Marques *e*t al.[31]also reported the role of glutamine in liver. They also demonstrated that the enzyme GST, which detoxifies and metabolizes foreign compounds, inactivates harmful metabolites by conjugation with reduced glutathione, thereby protecting cells from both exogenous and endogenous metabolites. In their investigation, TAA administration boosted GST activity whereas glutamine administration lowered GST activity.

The results of the current study contradict those of the following study, De paiva Neto *et al.[32]*on rats subjected to laparotomy and closure of the hepatic duct and supplemented with 2% glutamine for 21 days. Glutamine treatment did not influence the diagnosis of liver enzymes or histological abnormalities (fibrosis, portal phlebitis, hepatitis, hepatocyte modifications, and bile duct proliferation) in rats with extrahepatic bile duct blockage.

Histopathological observations on section of mice liver sections related to (G4) group showed Significant improvement and liver

structure closer to normal., this is attributed to the fact that giving glutamine as a protective agent before exposure to CCL_4 was more effective in preventing the severe histopathological alterations, also due to glutamine's ability to enhance antioxidants, particularly increasing the availability of glutathione, which reduces free radicals, including glutamine's ability to suppress the expression of a-SMA and TGF-B in liver tissues and EMT in liver cells. Therefore, it is a possible mechanism involved in the prevention of liver fibrosis, the results of the current study are consistent with zhang *et al[33]*who reported that glutamine is an imported substrate for the synthesis of new glutathione, a powerful antioxidant that protects cells from lipid peroxidation. They also showed that glutamine supplementation increases the activity of antioxidant enzymes, including SOD, Gpx, and catalase.

Glutamine supplementation in the high-fat diet inhibited the activation of inflammatory pathways generated by obesity and decreased the priming of immune cell precursors toward a pro-inflammatory phenotype. Metabolic Benefits of Glutamine Supplementation. In male mice, obesity caused a dramatic shift in structure with less fat stored in peripheral tissues and in the bones. Glutamine administration alleviated high-fat diet-induced hyperplasia of epididymal white adipose tissue, improved glucose metabolism and increased bone quality. Additionally, a glutamine-enriched diet enhanced cellular metabolism in primary mAT-MSCs and mBMSCs by reestablishment of glutamine turnover and reduction of inflammation [34]

Histopathological observations on section of mice liver sections related to (G5) group showed Normal liver tissue free from changes ,, this is because glutamine is a naturally occurring amino acid in the body that participates in many metabolic processes and also acts as an antioxidant to maintain the body's balance.

These results in agreement with De Nòbrgea *et al.[35]*We did not see any advantageous or disadvantageous effects of glutamine supplementation on biomarkers including body mass, liver

In Press

enzyme levels, and histological and functional alterations in the liver. Glutamine is believed to be an endogenous constituent in all tissues and unlikely to be intrinsically harmful even at elevated concentrations.

Liver sections from control mice stained with **(PAS)** stain for demonstration the glycogen content showed normal homogenous distribution of fine glycogen granules .

The results of the current study are agree with Desoky [36]Periodic acid-Schiff (PAS) staining of liver slices from the control animals showed normal glycogen distribution in the central portions and portal regions of the hepatic lobules with increased staining affinity. The glycogen was acidophilic or magenta and the basement membranes were also red.

Another study to Arif *et al.[37]*Liver slices were stained with PAS dye and were examined under microscope to establish the presence of glycogen accumulation in the hepatocytes. The hepatic sections of the control group exhibited a typical and healthy microarchitecture of the liver. Glycogen was observed as a distinct purple red stain and cell nuclei were stained light blue. In addition, the central vein, hepatic sinusoids, portal vein and hepatocytes were all observed to be structurally intact.

Microscopic examination of mice liver sections from (CCl_4) group showed mild reduction in glycogen content within hepatocytes, this may be associated with the loss of functional capacity of liver cells to store and produce glycogen, and also with detrimental effects of free radicals generated by metabolism of CCl4. Moreover, lipid alterations due to imbalance in beta-oxidation metabolism lead to fatty acid deoxidation. Moreover, CCl4 promotes inflammatory response leading to the invasion of immune cells.

The study results agree with Boye *et al.[38]*in a PAS-stained liver slices of model rats showed cytoplasmic fat accumulation in both centrilobular (hepatocytes surrounding central vein) and periportal (hepatocytes around the portal triad) hepatocytes and also hepato-cytic localized cytoplasmic basophilia.Some cells were positive for pas and some cells exhibited decreasing levels of glycogen. Also, infiltration of glycogen-positive oval cells and well-differentiated hepatocytes with a hyaline appearance was seen in the portal triad region. Addi-tionally, showed lymphocytic infiltration.The partial reduction in glycogen may be related to enhanced lipogenesis.Furthermore, the significant buildup of vacuolar fat which pushes the nucleus to the periphery implies structural and functional failure in the hepatocytes.

Another study to Ishikawa *et al*[39] and Özerkan *et al.[40]* who reported , The liver of CCl4-exposed animals showed PAS-stained hepatocytes surrounding the central vein, although PAS-stained regions corresponding to necrotic areas that lost glycogen were also seen.This may be explained by the fact that the metabolism of CCl4 by hepatic microsome enzymes induces oxidative stress that results in damage to cellular lipids and injury to the liver cells that have lost their capacity to produce glycogen.

CCl4 causes hepatic steatosis by a variety of mechanisms, including increased synthesis of fatty acids and triglycerides, synthesis of cholesterol and phospholipids from acetate, decreased beta-

In Press

oxidation of fatty acids, the researcher also explained that the inflammatory lymphocytic infiltration may be related to a greater number of monocytes and lymphocytes, which is an immune and inflammatory response [41-42] Findings from microscopic observation on mice liver sections from (G3) Incomplete improvement; there were moderate deposits of

glycogen granules with a weakly positive PAS result.this may be due to the fact that in addition to conserving and lowering the glycogen depletion caused by damage, glutamine lowered the severity of liver injury and maintained the metabolic activities of the liver cells.

The study results agree with palit *et al.[43]* the researcher found an rise in glycogen content which may be attributed to the ability of glutamine to inhibit gluconeogenesis, decrease hepatic GLUT2 and promote glycolysis and glycogen synthesis . It also improved glucose tolerance and insulin sensitivity by boosting the production of a protein called adiponectin, which is produced by fat cells and helps to store glucose in cells.

More study was added to pitaloka *et al.[44]*that shown glutamine enhanced glycogen synthesis and repressed gluconeogenesis which may be correlated with the increased protein expression associated to the PI3K-Akt signaling pathway and decreased expression of G6PC and FOXO1 in hepatocytes.

Findings from microscopic observation on mice liver sections from (G4) significantly improvement and a strong positive PAS.this might be because glutamine protected liver cells in the critical processes and decreased the impacts of stress, hence reducing cell damage and programmed cell death and enhancing the retention of glycogen reserves in the cell's intracellular fluid.

The study results are agree with Olaniyi and Olatunji[45] In a study with rats, pregnant animals received L-glutamine (1 g/kg) for 19 days and were subsequently treated with fructose . Ingestion of fructose resulted in a decrease in the quantity of liver glycogen and a concomitant decrease in the activity of glycogen synthase which may have led to the accumulation of fat . However, glutamine raised the glycogen content that could be connected to the inhibition of the pyruvate dehydrogenase kinase 4, so boosting the glucose consumption and the efficiency of the liver glycogen storage.

Another study to Yang *et al.[46]* on mice She discovered that glutamine enhanced glycogen levels and PAS staining was more apparent than the alcohol-only group that had poor glycogen levels. This may be related to the fact that glutamine has antioxidant qualities and influences programmed cell death (apoptosis) preventing liver damage and consumption of glycogen.

Microscopic examination of mice liver sections from (G5) Natural glycogen deposition and strong PAS staining. it is considered a fundamental energy source, and it may also enhance the activation of the glycogenolysis pathway by improving the performance of liver cells and increasing their ability to convert glucose into glycogen

The study results agree Miranda *et al.[47]*In a research on mice given glutamine-enriched food for 20 days, glutamine alone exhibited greater PAS staining than the other groups employed .

In Press

In (G2) the study results showed a significant increase in the levels of liver enzymes ALT, AST, ALP at (P<0.001), this can be explained by the fact that CCl_4 is converted into byproducts that cause harmful effects on the liver, damaging the integrity of its cell membranes, consequently, its enzymes leak into the bloodstream, resulting in an observed increase in enzyme levels.

The findings of the current study in agreement with Tanvir *et al.[48*] who studied male rats and showed comparable rise in liver enzymes, this is due to the toxic effects of CCl4 on the liver that causes liver damage and cholestasis, and oxidative damage. Also agreed with those of Madbouly *et al.[49]*who treated mice with CCl4 at a dosage of 5 ml/kg twice weekly for 3 weeks and noticed a substantial rise in blood levels of the marker enzymes ALT, AST and ALP. The rise of these enzymes in CCl4-treated animals is due to the release of these enzymes in the circulation after rupture of the hepatocyte cell membrane which enhances cell membrane permeability and favors the migration of extracellular cytoplasmic enzymes Manca *et al.[50].*Another study to Domia *et al[51]* a substantial rise in the levels of ALT, AST, and ALP enzymes was reported which is also consistent with earlier studies Akinloye *et al.[52]* , this can be explained by the fact that the products of carbon tetrachloride metabolism can catalyze lipid peroxidation of the plasma membrane, which can trigger a cascade of reactions, resulting in the deterioration of the integrity of the cell membrane and the subsequent release of enzymes into the extracellular environment [53]]

In (G3) the study results showed a significant increase in the levels of ALP and AST enzymes at (P<0.001) However, no significant differences were observed in ALT compared to the control group. Improved ALT indicates glutamine's ability to alleviate toxic effects on the liver due to its antioxidant properties, while elevated AST is not only present in the liver but also in other organs such as the heart, kidneys, and muscles. In addition, the ALP enzyme remains elevated because it is closely related to the bile ducts. Therefore, glutamine may repair damage to liver tissue cells, but it does not improve damage to the bile ducts.

The findings of this study are consistent with the results of a study Shrestha *et al.[29]*on male mice injected 3 times a week for 10 weeks with 2 different dosages of glutamine (0.25 g/kg and 0.5 g/kg) for 4 weeks revealed a reduction and improvement in the ALT enzyme compared to the CCl4 group. However, data for additional enzymes were not provided, the reduction in ALT was explained by the fact that glutamine is a primary precursor of the antioxidant glutathione, which decreases free radical-induced oxidation and maintains the integrity of cell membranes. It also lowered TGF-β1 and α-SMA which are associated with liver fibrosis and, thus, resulted in the reduced severity of damage. This improves liver health and improves liver enzyme levels. The findings of the present research are somewhat compatible with the following investigations.

A research by Chand[54] was conducted on mice in which acute liver damage was generated by a single intraperitoneal dose of CCl4 followed three successive subcutaneous doses of glutamine (GLN). The levels of aminotransferase enzymes (ALT and AST) were decreased in a dose-

In Press

dependent manner as compared with the CCl4 group. However, in our research the ALT was nearer to normal while the AST and ALP were still raised, this may be related to the dosage and duration of glutamine delivery.

Another study to shcemitt *et al.[55]* who reported that glutamine reduced the levels of the liver enzymes ALT, AST, and AlP in the blood serum, this may be attributed to glutamine's ability to activate the cellular stress mediator Nrf2, which translocates to the nucleus and binds to DNA via a region known as the antioxidant response element (ARE). This enhances the expression of target genes for cell protection, including antioxidant and detoxification enzymes. Where the gene promoted increased nuclear expression of the Nrf2 protein.While the cytoplasmic expression of the inhibitory protein Keap1 decreased, glutamine also enhanced the expression of the NQO1 protein and the antioxidant enzyme SOD. Furthermore, glutamine increased GSH levels in liver tissue, leading to reduced inflammation and cell membrane damage, which in turn improved enzyme levels.

The study contradicted with katoch et al.[56] on male rats with sickle cell anemia, L-glutamine was administered at a dose of 10–12 mg/mL in their drinking water for 8 weeks. These rats reported no improvement in serum markers of liver injury (ALT, AST, and ALP) after L-glutamine treatment. The researcher found that this was due to the advanced disease damage, with ongoing vascular occlusion and Cowper cell hyperplasia, meaning that glutamine was unable to improve the damage to the required extent. Consequently, liver enzyme levels did not improve.

In G4 the study showed a significant increase in ALP at ($P<0.001$), while no significant differences were observed in the levels of the enzymes ALT and AST compared to the control group, the improvement in liver enzymes ALT and AST indicates the protective efficacy of glutamine in safeguarding liver cells from free radicals, thus protecting cell membranes from leakage into the bloodstream. While ALP remains elevated, which is more closely associated with bile ducts, this suggests that glutamine protects liver cells, however, it may not be sufficient to treat cholestasis caused by CCl_4 .

The findings of the present investigation are in agreement with the work of chand[54]that generated chronic liver damage by intraperitoneal injection of carbon tetrachloride (CCl_4) three times weekly for ten weeks followed by dose-dependent glutamine administration for four weeks after injury. ALP levels were not recorded although ALT and AST levels dropped, the researcher attributed these findings to an effect of glutamine in inhibiting the levels of MDA and increasing the levels of GSH, furthermore, the decreased apoptotic pattern compared with the CCl4 treatment group implies a protective effect of glutamine on the CCl4induced hepatocyte damage. The findings of this current study somewhat accord with the following study by Adikwu *et al.[57]* who reported that glutamine was a reduction in the levels of ALP, AST and ALP compared to the control group, but that was different from our findings where ALP reduced while it grew in our present investigation, the researchers credited the reduction in these enzymes to the stabilizing effect of glutamine on the membranes of liver cells which may have prevented leaking of these indicators

In Press

into the circulation. The hepatic oxidative stress generated by BPA might be prevented by glutamine with its antioxidant action (glutathione) [58]. Moreover, glutamine might have repaired liver tissue by stimulating hepatocyte regeneration, development and repair, causing improvements in liver enzymes in its cells.

In another study Hu *et al.[59]*in male mice, glutamine lowered plasma levels of liver dysfunction indicators such as ALT, AST and LDH when compared to control group. ALP, however, did not suffer. The researchers interpreted this reduction as a reduction in the production of cleaved caspase-3, thereby reducing the formation of reactive oxygen species in the liver by improving the activity of SOD and GPX as well as GSH levels . Importantly, ALA dramatically decreased the number of phagocytic cells in the liver and inhibited the generation of inflammatory cytokines. All of these elements promote the health of the hepatocyte

In G5 the study results showed no significant changes or differences in liver enzymes ALT, AST, and ALP compared to the control group, this is attributed to the fact that glutamine has not had a toxic effect in the current dosage and duration, thus keeping liver cell membranes intact and preventing leakage into the bloodstream. It is also considered a natural amino acid.

The findings of a research Da Rosa *et al.[60]*conducted with healthy rats administered L-glutamine at a level of 248 mg/kg for 30 days are comparable with those of a similar study. It is safe for liver tissues and cells, with no notable alterations seen in liver enzymes.

In another study on big rats aged 27 months, they were given an intermittent glutamine supplement for 10 months to[61]They reported no changes in liver enzymes vs a control, which means no positive or negative alterations hepatotoxicity .

Limitations and Future Suggestions

The current study has provided supportive biochemical and histological evidence that confirms the protective and therapeutic efficacy of glutamine in carbon tetrachloride induced hepatotoxicity in mice. Nevertheless, the study has its limitations to be noted: First, although there are many studies that have looked at the molecular effects of glutamine, this study only correlated serum biochemical markers with histopathological changes.in liver cells without directly measuring gene expression for cytokines or cell death pathways (such as caspases) in the mouse samples relevant to this particular experiment. Second, the present study was conducted *in vivo* in mice, and although the data are correct, further translational studies in humans are needed to enable direct clinical use, taking into account inter-species differences in metabolic pathways. Thus, we suggest the following for future research: Complementary studies

(histological assessment, gene expression analyses (RT-PCR)) to validate the pathways involved. To further study the pharmacokinetics of glutamine to determine the optimal dosages to achieve the same histological efficacy observed here before moving to clinical trials.

Conclusions:The present study results indicate the protective and therapeutic effects of glutamine, against the CCl4- induced liver injury . The protective efficacy of glutamine was more

In Press