ASPI | Afarand Scholarly Publishing Institute; Turkey
ISSN: 2008-2630 *Iranian Journal of War & Public Health* 2023;15(3):257-262 10.58209/ijwph.15.3.257

Splinting in Congenital Hand Anomalies; A Systematic Review

ARTICLE INFO

Article Type
Systematic Review

Authors
Pashmdarfard M. [1] *PhD*
Kalantari M. [1]* *PhD*

How to cite this article
Pashmdarfard M, Kalantari M. Splinting in Congenital Hand Anomalies; A Systematic Review. Iranian Journal of War & Public Health. 2023;15(3):257-262.

[1] "Physiotherapy Research Center" and "Department of Occupational Therapy, School of Rehabilitation", Shahid Beheshti University of Medical Sciences, Tehran, Iran

***Correspondence**
Address: Department of Occupational Therapy, School of Rehabilitation, Shahid Beheshti University of Medical Sciences, Damvand Street, Tehran, Iran. Postal Code: 1616913111
Phone: +98 (21) 77542057
Fax: +98 (21) 77591807
mn_kalantari@yahoo.com

Article History
Received: August 9, 2023
Accepted: September 18, 2023
ePublished: October 2, 2023

ABSTRACT

Aims Congenital hand anomalies are abnormal conditions presented at birth regardless of their cause. These abnormalities may lead to structural or functional disorders in children. The treatment of pediatric hand anomalies has been controversial, and the agreement on the gold standard for the treatment of this malformation in children has yet to be ambiguous.
Information & Methods The aim of the present study was to review studies on splinting in congenital hand anomalies using ProQuest, PubMed, Scopus, and EMBASE databases published from 1990 to 2023.
Findings A total of 344 articles were found and finally, 13 articles were reviewed, of which six cases were at evidence level I (one randomized controlled trial (RCT) and five reviews), two cases were at evidence level II, two cases were at evidence level III, one study was at evidence level IV, and two cases were at evidence level V. The methodological quality assessment of the one and five included RCTs and systematic review studies showed the moderate-to-high quality of the studies based on the scores≥5 using the Physiotherapy Evidence Database (PEDro) and Assessment of Multiple Systematic Reviews (AMSTAR) scales.
Conclusion The use of a splint alone in the function of the upper limbs of children suffering from congenital hand abnormalities cannot be presented as an effective solution.. The use of splints as the first line of congenital hand anomalies in children can be useful if prescribed during infancy and in some congenital anomalies, such as thumb and radial hand. The best treatment process for children with other hand anomalies is surgery and timely prescription of a splint.

Keywords Splints; Adult Children; Hand; Abnormalities; Review

CITATION LINKS

[1] Treatment of congenital upper ... [2] Congenital hand anomalies: A review of the ... [3] The effect of splinting after Dupuytren's contracture operation: A ... [4] Inter-and intra-rater reliability of the Oberg-Manske-Tonkin classification of congenital ... [5] The Oberg-Manske-Tonkin (OMT) classification of congenital upper extremities ... [6] Views on the Oberg-Manske-Tonkin classification system for congenital anomalies ... [7] Congenital thumb anomalies and the consequences for daily life: Patients' long-term experience after corrective ... [8] The importance of embryology for parents of children with congenital ... [9] Upper limb congenital muscular hypertrophy and aberrant muscle ... [10] The biopsychosocial model of illness: A model whose time has ...[11] Early intervention to improve hand function in hemiplegic ... [12] Impact of extension splint on upper extremity motor components and function in chronic ... [13] Surgery and conservative management of camptodactyly in pediatric patients: A ... [14] Treatment alternatives of congenital hand differences with thumb ... [15] Conservative treatment of pediatric trigger thumb: Follow-up for ... [16] AOTA's evidence-based literature review project: An ... [17] Preferred reporting items for systematic review and meta-analysis protocols (PRISMA-P) ... [18] Evidence-based medicine: A science of uncertainty and an art ... [19] AMSTAR 2: A critical appraisal tool for systematic reviews that include randomised or non-randomised studies of ... [20] Clinimetrics: Physiotherapy Evidence ... [21] Systematic review and meta-analysis of therapeutic management of upper-limb ... [22] Hand therapy for children with congenital ... [23] Arthrogryposis multiplex ... [24] Arthrogryposis wrist deformities: Results ...[25] Serial casting and splinting of elbow contractures in children with obstetric ... [26] Evaluation and management of preaxial [27] Extension splint for trigger thumb in ... [28] Syndactyly correction of the hand in ... [29] Neoprene wrist brace for correction of radial ... [30] A simple splinting method for correction of supple congenital clasped ... [31] Splinting in arthrogryposis multiplex ... [32] Parents' experiences of splinting programs for babies with congenital ... [33] Rehabilitation post-distraction osteogenesis for ... [34] Surgical management of hand deformities in patients with recessive ...

Copyright© 2023, the Authors | Publishing Rights, ASPI. This open-access article is published under the terms of the Creative Commons Attribution-NonCommercial 4.0 International License which permits Share (copy and redistribute the material in any medium or format) and Adapt (remix, transform, and build upon the material) under the Attribution-NonCommercial terms.

Introduction

Hand anomaly can be congenital or acquired as a result of neurological damage to the central nervous system during the childhood process [1]. Most hand deformities in children are known as a congenital disorder, or an abnormal condition that is present at birth regardless of its cause [2]. These abnormalities may lead to structural disorders, in which problems are seen in the appearance of a body part, or functional disorders, in which there are problems in the way a part of the body functions [3]. However, the above-mentioned classification has been updated over several periods, and the last updated classification is related to 2020 [4].

In 2010, for the first time, a new classification for upper limb congenital malformations was published under the title of Oberg-Manske-Tonkin (OMT) [5]. Based on a malformation framework, OMT is accepted by the International Federation of Hand Surgery Society and surgeons treating congenital anomalies of the upper extremities. According to the updated OMT classification, upper extremity abnormalities fall into one of the categories of malformations, deformities, dysplasias, and syndromes [6].

Congenital malformations and anomalies of the upper limb, with a reported overall prevalence of 21.5 out of 10,000 live births, may have serious consequences for any patient [7]. The causes of congenital abnormalities in children are unknown in 60% of cases [8]. The greatest effect of congenital anomalies is observed in the fingers, followed by the forearm area, and finally, in the upper parts, such as the arm [9].

The International Classification of Functioning, Disability, and Health (ICF) provides a framework that describes the interrelationship between body function and structure, activities, and participation, as well as the influence of environmental and personal factors [10]. In the meantime, hand function in children with congenital anomalies of the upper limb can lead to a vicious cycle in body structure, function, activity, or participation in different areas of life. However, early and timely interventions in this vicious cycle can create hope to break this vicious cycle and promote children's participation [11].

Performing activities of daily living (ADL) requires the hands to perform different movements in a coordinated manner at the same time [12]. In the meantime, congenital anomalies in the upper limbs, especially in children, lead to emotional stress, failure in manual functions related to ADLs, and a feeling of low self-confidence in the presence of peers and family, which ultimately may affect the life satisfaction and long-term well-being of children [13].

To date, the treatment of pediatric hand malformations has been controversial, and agreement on the gold standard for the treatment of this malformation in children has yet to be reached [14]. Although some hand deformities in children are currently treated with surgery, some researchers have considered success with conservative treatment, including the use of splints, rehabilitation, drug therapy, or the use of assistive technologies [15]. We assessed the effect of using splints on improving the hand function of children under 18 years old with all kinds of anomalies of the hands.

Instrument and Methods

We used the systematic evidence-based review process [16] and followed the Preferred Reporting Items for Systematic Reviews and Meta-Analyses (PRISMA) guidelines for systematic review studies [17]. ProQuest, PubMed, Scopus, and EMBASE databases were searched using the following keywords: Orthosis, Splint, Brace, Hand, Upper extremity, Congenital Anomalies, Children, and Pediatric. The Boolean operators "AND" and "OR" were also used to combine and define the relationship between these search terms; for example, "Hand Orthosis AND children".

Inclusion and exclusion criteria

Articles included in this study were published in peer-reviewed journals, assessed congenital hand anomalies and orthotic intervention, consisted of hand anomalies based on the OMT classification system of hand anomalies, and were published in the English language from 1990 to 2023. The included articles showed the I, II, III, IV, and V levels of evidence based on the evidence-based model [16, 18]: Level I: randomized controlled trials (RCTs), systematic reviews, meta-analyses, level II: nonrandomized studies (cohorts and case controls) using two groups, level III: nonrandomized studies with one group (e.g., pre-test–post-test stage), level IV: descriptive studies that included the analysis of outcomes (e.g., single-subject design and case series), level V: case reports and expert opinion that included narrative literature reviews and consensus statements. We excluded theses, presentations, and conferences.

The search was undertaken between July 6, 2023, and August 5, 2023. Two researchers (the first author and the second independent researcher) searched and screened the articles individually based on titles, abstracts, and full-text examination. They found 344 articles and screened the articles together again, and after removing duplicate articles, 131 articles remained. These articles were screened by the first and second authors based on the eligibility criteria. The following articles were removed: assessing orthotic interventions in adults and older adults (n=48), the full text was not available (n=22), the language was other than English (n=16), assessing participants with other deformities rather than hand anomalies (n=25), and studies published before 1990 (n=7). Of the 13 remaining articles, 13 articles were found eligible by both authors (an agreement rate of

92%). To assess the agreement rate between the two researchers, the second author screened the articles and confirmed meeting the eligibility criteria for this study. Any disagreements were resolved by discussion with the second author.

Methodological quality of the included studies

The methodological quality of the included systematic reviews was assessed by the Assessment of Multiple Systematic Reviews (AMSTAR) checklist (Table 1).

A score of one was recorded for each criterion present, with a total possible score of 11. The AMSTAR has good face and content validity [19]. The methodological quality of the included trials was evaluated by the Physiotherapy Evidence Database (PEDro) scale. This scale has 11 criteria, each scored as zero or one, resulting in a possible total score of 11. The interrater reliability of the PEDro scale is adequate [20]. Table 1 presents the results of the methodological quality assessment of the one and five included RCT and systematic review studies, respectively. All included trials had moderate-to-high quality with scores ≥5 on the PEDro scale. Also, all included reviews had moderate-to-high quality with scores ≥5 based on the AMSTAR scale.

Table 1. The methodological quality of the included systematic reviews using the AMSTAR checklist and randomized controlled trials using the PEDro Scale

Study	1	2	3	4	5	6	7	8	9	10	11	Total score
Lake [22] (Review)	1	1	1	0	0	1	1	0	0	0	0	5
O'Flaherty [23] (Review)	1	1	1	0	1	0	1	0	0	0	0	5
Smith and Drennan [24] (Review)	1	1	1	0	0	1	1	0	0	0	0	5
Ho *et al.* [25] (Review)	1	1	1	0	1	0	1	0	0	0	0	5
Rogers *et al.* [26] (Review)	1	1	1	0	1	1	1	0	0	0	0	6
Lee *et al.* [27] (Randomized controlled trial)	1	1	1	1	0	0	0	1	0	0	1	6

Findings

Selection of articles

Among 13 selected articles, six cases were at evidence level I (one RCT and five reviews), two cases were at evidence level II, two cases were at evidence level III, one was at evidence level IV, and two cases were at evidence level V (Figure 1). The description of the included 13 studies is presented in Table 2.

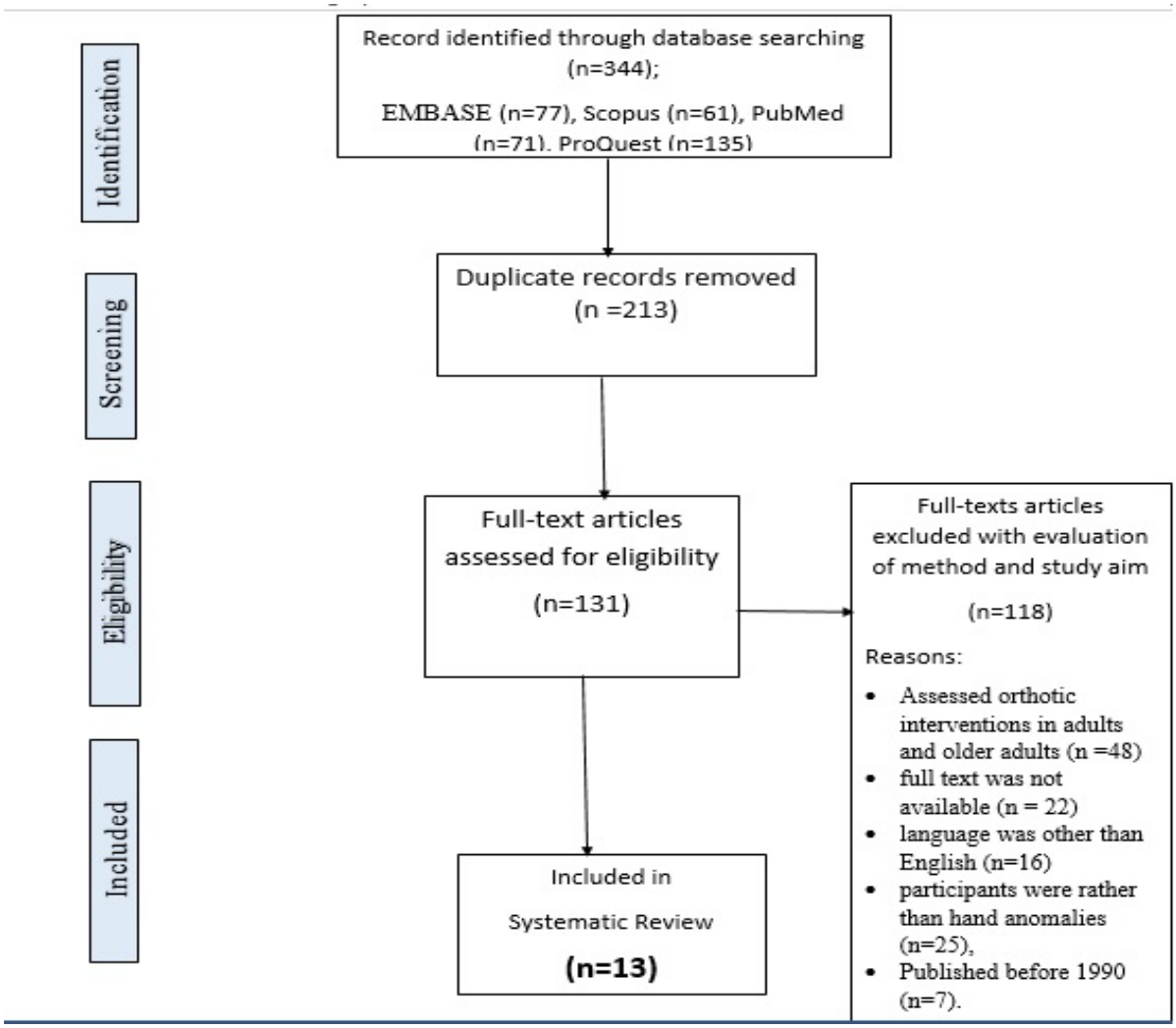

Figure 1. PRISMA flow diagram

Table 2. Results of the included articles (n=13)

Study	Year	Diagnosis	Type of study	Type of splinting	Sample size, participants' age, surgery: yes/no	Results
Zucker *et al.* [28]	1991	Apert Syndrome	Experimental	Thermoplastic (static) splint	N=18 5 months -11 years Surgery: yes	The first treatment of Apert syndrome is surgery, which should be done when the child is 6 months old. After surgery for maintaining the correction, using the static splint is necessary.
Kennedy [29]	1996	Radial club (radial dysplasia)	Case-control	Thermoplastic (static) splint	N=9 3 weeks -9 years Surgery: no	The use of neoprene hand splints was effective in maintaining the condition of these children's hands, and long-term use was more effective.
Lin *et al.* [30]	1999	Congenital clasped thumb of the supple type	Experimental	Thermoplastic (static) splint	N=11 infant (17 thumbs) 3 to 12 months Surgery: yes	The functional results were excellent in 15 of 17 thumbs, and the other two were good according to the grading system of Weckesser *et al.*
O'Flaherty [23]	2000	Arthrogryposis multiplex congenita (AMC)	Review	Thermoplastic (static) splint	N=24 3-12 years Surgery: yes	Since joint stiffness does not have a bone cause, using splints as stretching exercises and increasing the joint range of motion after surgery was effective.
Smith and Drennan [24]	2002	AMC	Review	Custom static splint	N=17 0-6 years Surgery: no	In younger children, the early use of splints can be effective, but in older children, other treatment measures should also be considered.
Katić *et al.* [31]	2002	AMC	Case report	Thermoplastic (static) splint	N=1 An infant Surgery: no	Early administration of splints in these children for at least six months has a significant effect on preventing the shortening of these children's joints.
Lee *et al.* [27]	2006	Trigger thumbs	RCT	Thermoplastic (static) splint	N=50 children with 62 trigger thumbs 2 months-4 years Surgery: no	The use of splints in these children for three months reduced the stiffness of the joints and prevented the reduction of the range of motion caused by the disease.
Lake [22]	2010	Congenital hand differences	Review	Static and dynamic splints	N=26 0-18 years Surgery: no	The effectiveness of splints highly depends on acceptance and non-acceptance by people. The highest admission was in infants less than six months and children aged 7 to 12 years and the lowest admission in toddlers 18 months to 4 years and teenagers.
Ho *et al.* [25]	2010	Obstetric brachial plexus palsy (OBPP)	Retrospective review	Thermoplastic (static) night splint	N=19 2-16 years Surgery: no	The use of splints in younger children showed more favorable and acceptable results.
Durlacher *et al.* [32]	2015	Congenital limb (upper extremity) anomalies	Qualitative study	Static splint	N=10 10-23 month Surgery: no	The use of splints, especially after surgery, requires support and educational interventions for families and children.
Ho *et al.* [33]	2017	Brachymetacarpia	Case report	Thermoplastic night splint and anti-swan neck splint	N=1 13 years old Surgery: yes	The use of splints up to 28 weeks after surgery along with other therapeutic modalities, such as desensitization, scar massage, and range of motion exercises was effective and efficient.
Zhou *et al.* [34]	2019	Recessive dystrophic epidermolysis bullosa (RDEB)	Retrospective study	thermoplastic (static) splint	N=11 4-24 years old Surgery: yes	Using a splint after surgery in RDEB patients is an effective approach to improving the abnormalities of these patients.
Rogers *et al.* [26]	2020	Preaxial polydactyly	Review	Thumb spica splint	N=14 0-4 years Surgery: yes	Using splints before and after surgery in these children can bring effective results.

Discussion

The purpose of this study was to review the effect of using upper limb splints on the hand function of children with various congenital hand anomalies. Based on the updated OMT classification, deformities are also classified as upper limb abnormalities [5]. In the present study, out of the 13 included studies, six studies were at evidence level I [22-27], two studies were at evidence level II [29, 34], two studies were at evidence level III [28, 30], one study was at evidence level IV [32], and two studies were at evidence level V [31, 33]. In most aforementioned studies, surgery was identified as the first line of treatment for congenital anomalies in these children, and the use of splints was considered a complementary treatment after surgery for children.

In the study by Zhou *et al.*, surgery in children with recessive dystrophic epidermolysis bullosa (RDEB) greatly affected the children's hand function when immediately after the mentioned surgeries, the child used a splint [34]. Rogers *et al.* also stated that the first-line treatment in children with preaxial polydactyly is surgery. Surgery for children with preaxial polydactyly and timely prescription of splints, especially thumb spica splints, was presented as the most effective treatment method for these children [26]. However, Ho *et al.* regarding the first line of treatment in children with obstetric brachial plexus palsy (OBPP) suggested that serial casting and the use of splints can have the best effect, especially in young children. Contracture between 20° and 40°, as well as contracture of less than 20°, can achieve better results from splinting and serial casting [25]. Ho *et al.* in a case report assessed a 13-year-old girl with brachymetacarpia, for whom the combination of surgery and post-surgical interventions, including scar tissue massage, therapeutic exercises, and the use of splints were provided as complementary treatments. Night composite extension splint (a thermoplastic night splint) and anti-swan neck splint during the day after surgery showed the best outcomes for children with brachymetacarpia [33].

In the study by Lee *et al.*, splinting was suggested as the first line of treatment for non-fixed trigger thumb in children under one year, and surgery for the first line of treatment for fixed trigger thumb in children [27]. Kennedy suggested that for congenital anomalies, such as radial club hand, the first-line treatment is the use of splints, especially the neoprene splint. Because babies welcome splints more at birth, flexibility in muscles and joints provides a good opportunity and possibility for treatment with splints. Surgery is recommended for children after three years who are fixed with a radial club hand [29].

Zucker *et al.* suggested that the first-line treatment for syndactyly correction of the hand in children with Apert Syndrome is surgery, which should be conducted when the child is six years old. After surgery, maintaining the correction using the static splint is necessary [28].

The use of splints as first-line or maintenance therapy for better surgical outcomes in children with arthrogryposis multiplex congenital (AMC) has been supported by multiple studies [23, 24, 31]. O'Flaherty considered surgery the first-line treatment in AMC children and mentioned that stretching, serial casting, and splints as post-surgical maintenance interventions to increase the range of motion in the joints [23]. Smith and Drennan [24] and Katić *et al.* [31] reported that serial casting and splinting increase the range of motion in the joints and are the first-line treatment in AMC infants. Nevertheless, it can be said that in newborns with AMC, it is better to try to increase the range of motion of the joints with interventions, such as serial casting and splinting, and prevent fibrosis of the joints, and in older children up to six months and above, interventions, like surgery is recommended.

Conclusion

Based on the results of the present study, it can be said that the use of splints alone cannot be an effective solution for the function of the upper limbs of children with a variety of congenital hand disorders and abnormalities. The use of splints as the first line of congenital hand anomalies in children can be useful if prescribed during infancy and in some congenital anomalies, such as thumb and radial hand. Splinting is most effective when used in conjunction with other evidence-based interventions, such as surgery, and evidence-based interventions in rehabilitation. The best treatment for children with hand anomalies is surgery and timely prescription of splint use.

Acknowledgments: We are grateful to the officials of the School of Rehabilitation Sciences at Shahid Beheshti University of Medical Sciences and those who helped us with this research.

Ethical Permission: This is a review article with no human or animal sample.

Conflicts of Interests: The authors declared no conflicts of interests.

Authors' Contribution: Pahmdarfard M (First Author), Introduction Writer/Methodologist/Original Researcher (50%); Kalantari M (Second Author), Assistant Researcher/Discussion Writer/Statistical Analyst (50%)

Funding/Support: This research did not receive any grant from funding agencies in the public, commercial, or non-profit sectors.

References

1- Netscher DT, Baumholtz MA. Treatment of congenital upper extremity problems. Plast Reconstr Surg. 2007;119(5):101e-29.

2- Goldfarb CA. Congenital hand anomalies: A review of the literature, 2009-2012. J Hand Surg Am. 2013;38(9):1854-9.

3- Pashmdarfard M, Azad A, Amini M, Golabi G. The effect of splinting after Dupuytren's contracture operation: A systematic review. Iran Rehabil J. 2019;17(4):297-304.

4- Sletten IN, Winge MI, Hülsemann W, Arner M, Hansen KL, Jokihaara J. Inter-and intra-rater reliability of the Oberg-Manske-Tonkin classification of congenital upper limb anomalies. J Hand Surg Eur Vol. 2022;47(10):1016-24.

5- Goldfarb CA, Ezaki M, Wall LB, Lam WL, Oberg KC. The Oberg-Manske-Tonkin (OMT) classification of congenital upper extremities: Update for 2020. J Hand Surg. 2020;45(6):542-7.

6- Lowry RB, Bedard T, Kiefer GN, Sass KR. Views on the Oberg-Manske-Tonkin classification system for congenital anomalies of the hand and upper limb. J Hand Surg Am. 2017;42(5):378-81.

7- Carlsson IK, Dahlin LB, Rosberg HE. Congenital thumb anomalies and the consequences for daily life: Patients' long-term experience after corrective surgery. A qualitative study. Disabil Rehabil. 2018;40(1):69-75.

8- Clelland AD, Duncan Ó, Lam WL. The importance of embryology for parents of children with congenital hand differences. J Hand Surg Eur Vol. 2022;47(5):475-80.

9-Dahan E, Chaves C, Bachy M, Fitoussi F. Upper limb congenital muscular hypertrophy and aberrant muscle syndrome in children. J Hand Surg Eur Vol. 2018;43(7):751-5.

10- Wade DT, Halligan PW. The biopsychosocial model of illness: A model whose time has come. Clin Rehabil. 2017;31(8):995-1004.

11- Basu AP, Pearse J, Kelly S, Wisher V, Kisler J. Early intervention to improve hand function in hemiplegic cerebral palsy. Front Neurol. 2015;5:281.

12- Amini M, Moosavi S, Shamily A, Kazemi R, Qorbani M, Pashmdarfard M. Impact of extension splint on upper extremity motor components and function in chronic stroke patients. Iran Rehabil J. 2014;12(19):18-21.

13- Wang AM, Kim M, Ho ES, Davidge KM. Surgery and conservative management of camptodactyly in pediatric patients: A systematic review. Hand. 2020;15(6):761-70.

14- Papadogeorgou EV, Soucacos PN. Treatment alternatives of congenital hand differences with thumb hypoplasia involvement. Microsurgery. 2008;28(2):121-30.

15- Jung HJ, Lee JS, Song KS, Yang JJ. Conservative treatment of pediatric trigger thumb: Follow-up for over 4 years. J Hand Surg Eur Vol. 2012;37(3):220-4.

16- Lieberman D, Scheer J. AOTA's evidence-based literature review project: An overview. Am J Occup Ther. 2002;56(3):344-9.

17- Moher D, Shamseer L, Clarke M, Ghersi D, Liberati A, Petticrew M, et al. Preferred reporting items for systematic review and meta-analysis protocols (PRISMA-P) 2015 statement. Syst Rev. 2015;4(1):1-9.
18- Rysavy M. Evidence-based medicine: A science of uncertainty and an art of probability. Virtual Mentors. 2013;15(1):4-8.
19-- Shea BJ, Reeves BC, Wells G, Thuku M, Hamel C, Moran J, et al. AMSTAR 2: A critical appraisal tool for systematic reviews that include randomised or non-randomised studies of healthcare interventions, or both. BMJ. 2017;358.
20- Cashin AG, McAuley JH. Clinimetrics: Physiotherapy Evidence Database (PEDro) Scale. J Physiother. 2019;66(1):59.
21- Sakzewski L, Ziviani J, Boyd R. Systematic review and meta-analysis of therapeutic management of upper-limb dysfunction in children with congenital hemiplegia. Pediatrics. 2009;123(6):e1111-22.
22- Lake A. Hand therapy for children with congenital hand differences. Tech Hand Up Extrem Surg. 2010;14(2):78-84.
23- O'Flaherty P. Arthrogryposis multiplex congenita. Neonatal Network. 2001;20(4):13-20.
24- Smith DW, Drennan JC. Arthrogryposis wrist deformities: Results of infantile serial casting. J Pediatr Orthopaedics. 2002;22(1):44-7.
25- Ho ES, Roy T, Stephens D, Clarke HM. Serial casting and splinting of elbow contractures in children with obstetric brachial plexus palsy. J Hand Surg. 2010;35(1):84-91.
26- Rogers BH, Schmieg SL, Pehnke ME, Shah AS. Evaluation and management of preaxial polydactyly. Curr Rev Musculoskeletal Med. 2020;13:545-51.
27- Lee ZL, Chang CH, Yang WY, Hung SS, Shih CH. Extension splint for trigger thumb in children. J Pediatr Orthopaedics. 2006;26(6):785-7.
28- Zucker RM, Cleland HJ, Haswell T. Syndactyly correction of the hand in Apert syndrome. Clin Plast Surg. 1991;18(2):357-64.
29- Kennedy SM. Neoprene wrist brace for correction of radial club hand in children. J Hand Ther. 1996;9(4):387-90.
30- Lin N SC, Huang TH, Hsu HY, Lin CJ, Chiu HY. A simple splinting method for correction of supple congenital clasped thumbs in infants. J Hand Surg. 1999;24(5):612-4.
31- Katić D, Anticević D, Grgurev S, Jukica M, Katić M. Splinting in arthrogryposis multiplex congenita. Lijecnicki Vjesnik. 2002;124(3-4):77-81.
32- Durlacher KM, Verchere C, Zwicker JG. Parents' experiences of splinting programs for babies with congenital limb anomalies. J Pediatr Rehabil Med. 2015;8(3):207-17.
33- Ho ES, Bradley CS, Borschel GH, Kelley SP. Rehabilitation post-distraction osteogenesis for brachymetacarpia: A case report. Strategies Trauma Limb Reconstruction. 2018:1-5.
34- Zhou X, Zhang Y, Zhao M, Jian Y, Huang J, Luo X, et al. Surgical management of hand deformities in patients with recessive dystrophic epidermolysis bullosa. J Plast Surg Hand Surg. 2020;54(1):33-9.