



Peculiarities of Clinical and Morphological Characteristics of Patients on the Local-advanced Malignant Tumors of the Thyroid Gland

ARTICLE INFO

Article Type

Original Research

Authors

Deineko I.*¹ PhD

How to cite this article

Deineko I. Peculiarities of Clinical and Morphological Characteristics of Patients on the Local-advanced Malignant Tumors of the Thyroid Gland. Iranian Journal of War & Public Health. 2022;14(3):257-262.

ABSTRACT

Aims The main purpose of the study is to study and compare clinical and morphological characteristics, as well as the results of comprehensive treatment of patients with locally advanced malignant thyroid tumors T4a and T4b stage, compared with tumors without T1-3 invasions, to determine the main factors influencing the prognosis disease.

Material & Methods The study groups included 120 patients with invasive locally-advanced malignant tumors of the thyroid gland of category T4a and 35 patients of category T4b. Also, for comparison of general and morphological characteristics, the control group of patients with non-invasive locally-advanced malignant tumors of the thyroid gland, or with the initial invasion of pre-thyroid muscles of category T1-3, which made up 1985 patients, was studied.

Findings It was found that depending on the prevalence and degree of tumor invasion, the average age of patients increased, the number of men in groups increased, and the number of patients with regional and distant metastases increased, which worsened the prognosis. The most frequent localization of the invasion of the tumor of the thyroid gland was the invasion in the upper respiratory tract, namely, the invasion in the trachea, due to the close location of the thyroid gland around the trachea.

Conclusion Aggressive surgical interventions in complex treatment allows in cases of well-differentiated tumors to significantly improve survival rates and reduce recurrence. Also, the use of radical methods of surgery improved the efficiency of treatment of the moderately differentiated tumors of the thyroid gland. Not looking at the use of aggressive radical surgery in the complex treatment of patients, the worst indicators remain in cases of moderate and poorly differentiated forms of the disease, but significantly improved quality and life expectancy, which is also important in cases of low morphological structure.

Keywords Thyroid Cancer; Neoplasm Invasiveness; Neck; Mediastinum; Treatment Outcome

CITATION LINKS

[1] Metabolic processes of organism in remote period after the combined ... [2] Cancer in Ukraine ... [3] Multiple organ dysfunction syndrome ... [4] 2015 American Thyroid Association ... [5] The frequency, dynamics, and structure of ... [6] The state of proinflammatory and anti-inflammatory ... [7] Thyroid cancer screening in South Korea increases ... [8] Clinical presentation and diagnostic challenges of thyroid ... [9] Surgical treatment of locally advanced ... [10] Case report: lenvatinib in neoadjuvant setting in a patient affected ... [11] Thyroid cancer invading the airway: diagnosis and ... [12] Are prognostic scoring systems of value in patients with ... [13] WHO classification tumors of endocrine ... [14] Oncologic outcomes of pelvic bone ... [15] Surgical treatment in locally advanced ... [16] Surgical management and prognosis of ... [17] Prognostic value of the eighth edition ... [18] The surgical management of locally advanced ... [19] The content of some essential micronutrients ... [20] Research of the mechanism of recognition of ... [21] Strangulation of the penis: two ... [22] 2019 European Thyroid Association guidelines for the treatment and ... [23] Hyalinizing trabecular tumor of the thyroid ... [24] Single neonatal irradiation induces ... [25] Analysis of vascularization in thyroid gland nodes with ...

¹Endocrine Surgery Center, Dnipropetrovsk Regional Clinical Hospital named after. I.I. Mechnikov, Dnipro, Ukraine

*Correspondence

Address: 49005, 14 Soborna Sq., Dnipro, Ukraine

Phone: 056 746 2820

Fax: -

deineko9246@uohk.com.cn

Article History

Received: March 21, 2022

Accepted: May 27, 2022

ePublished: July 28, 2022

Introduction

Thyroid cancer accounts for up to 3% of all human cancers [1, 2]. In more than 90% of cases, there are highly differentiated, papillary, and follicular forms of thyroid gland cancer in the I-III stage of the disease, which have no large complications for the surgeon, and have a very good expected response to treatment [3, 4]. But in recent years, the incidence of not only high-differentiated thyroid cancer has increased twice over the last decade [5, 6], as well as the percentage of untreated malignant tumors of the thyroid gland with the extrusion spread of the medium and low morphological differentiation, respectively medullary, poorly differentiated, anaplastic cancer and primary lymphomas of the thyroid gland [7, 8].

The urgency of the problem is caused by the absence of a single therapeutic tactic for locally-advanced malignant tumors of the thyroid gland. Depending on the prevalence and histological differentiation of tumors, the choice of the volume of surgical intervention, from palliative and urgent symptomatic to "aggressive" super radical, the volume of resections of the upper respiratory tract, and the stage of closure of their defects, depending on the type of symptoms and the spread of the disease. The data presented in the reference list, apply to very small groups of patients (up to two-three dozen), which does not allow us to make certain conclusions about planning surgical interventions in the complex treatment.

The main goal of the research was to compare clinical and morphological characteristics, as well as results of complex treatment of patients with the local-advanced malignant tumors of the thyroid gland T4a and T4b stages, in line with tumors without invasive T1-3, to determine the main factors influencing the disease prognosis.

Materials and Methods

In this experimental research, from 2004 to October 2021, 2140 patients with malignant tumors of the thyroid gland were treated in the Department of Endocrine Surgery of the Mechnikov Hospital; 1198 patients (56,0%) were referred to category T1, 367 patients (17,1%) to T2, 420 (19,6%) to T3 and 155 patients (7,3%) to T4. The study groups included 120 patients with invasive locally-advanced malignant tumors of the thyroid gland of category T4a and 35 patients of category T4b. Also, for comparison of general and morphological characteristics, the control group of patients with non-invasive locally - advanced malignant tumors of the thyroid gland, or with the initial invasion of pre-thyroid muscles of category T1-3, which made up 1985 patients, was studied.

All patients were given standard methods of research; There are sonography of thyroid glands and organs and lymphatic nodes of the neck,

palpation of the neck, thin-needle aspiration puncture biopsy of the thyroid gland, tumor, and lymphatic nodes of the neck. Also, the sonography criteria of the Eu-Thirads system and the cytology criteria of the Bethesda system were taken into account. Hormonal studies (thyrotrophic hormone, free thyroxine, thyroglobulin and antibody to it, calcitonin), general and biochemical analyzes of blood with electrolytes, separate ionized calcium for the elimination of parathyroid gland carcinoma, coagulogram, electrocardiogram, radiologic studies organs of the thoracic cavity. The general condition of patients, anamnesis and chronic diseases necessary in each case of reexamination was assessed. In cases of clinical and sonography data for the invasion of tumors spiral computer tomography with contrast or magnetic-resonance tomography of the neck and organs of the thoracic cavity, doppler ultrasonography of arterial vessels of the neck and mediastinum, endoscopic research of throat, trachea, and esophagus was conducted. If a more precise histological structure of the tumor is needed, with doubtful cytological conclusions, for determination of the tactics of complex treatment, at the diagnostic stage it was conducted an incident biopsy of tumor or metastasis in the regional lymphatic node, or trepan-biopsy of the tumor [7]. Also, in cases of uncertain groups Bethesda III-IV, carried out molecular-genetic research of cytological material with the determination of mutations (BRAF, NRAS, KRAS, HRAS, 2RET/PTC, PAX8/PPARG) [8]. It is necessary to conduct histological, and if necessary immunohistochemically research of the removed material at operation, with a determination of the presence of tumor in edges of resection and metastases in lymphatic nodes.

The study was approved by the National Ethics Commission of the Ministry of Health of Ukraine. All procedures performed in studies involving human participants were under the ethical standards of the institutional and national research committee and with the 1964 Helsinki declaration and its later amendments or comparable ethical standards. For further comparison of research groups, and analysis of their prognosis of treatment, we also divided patients into 3 subgroups on the factor of morphological malignancy: well-differentiated tumors (papillary and follicular cancer), moderately differentiated tumors (medullary, oncocytic, and squamous cancer) and poorly differentiated tumors (low-differentiated and anaplastic cancer, B-cell lymphomas and rare types of tumors with high-grade malignant potential). All patients were treated with complex treatment with application in some patients of neoadjuvant antitumor poly-chemotherapy, a combination of different methods of radical or palliative surgical treatment, adjuvant therapy (radioiodine therapy or distant gamma-therapy), suppressive hormonal therapy at high-

differential cancer. At recurrence of the disease was carried out repeated surgical interventions, and rates of radiation therapy and antitumor poly-chemotherapy in some patients. There was also a long screening, at least 5 years with the definition of tumor markers, sonographic and radiological control studies with the study of recurrence, and 5-year survival rates.

Data processing and statistical analysis were carried out using the LibreOffice and R software packages (version 3.6.3). Quantitative indicators in the presented study were of the non-parametric type of distribution, so they were presented in results in the form of medical and 25 and 75 percentiles (IU [25%;75%]). The comparison of quantitative indicators between groups was carried out with the help of the criterion of Kraskela-Walesa. Qualitative data were presented in the form of frequency. Comparison of qualitative indicators was carried out with the help of the criteria of the Chi-square of Pirson without the correction of Yates for continuity. The critical level of p in the check of statistical hypotheses was adopted <0.05. There were no missing data in the presented study.

Findings

We have studied such general clinical and morphological characteristics of patients as age, the ratio of men to women, presence of local and remote metastases, stage of differentiation of tumors, indicators of recurrence and 5-year survival, these data are given in Table 1.

By analyzing the above factors, we have seen a clear, statistically reliable difference in the prevalence and invasion rates of primary tumors, in groups T4a and T4b were higher than the average age of the patients, and made up 57.7 (46.0±68.0) and 61.2 (45.5±65.5), respectively, in groups T1-3 48.4 (39.1±55.0). Much more were men, the ratio of men to women in groups T4a and T4b was 1:1.9 and 1:1.2, in comparison with the group of patients T1-3 – 1:5.

Table 1) The clinical and morphological characteristics of patients in the experimental groups (numbers in the parenthesis are in percent)

Index	Group		
	T1-3 (n=1985)	T4a (n=120)	T4b (n=35)
Sex			
Men	335 (16.7)	42 (37.5)	16 (45.7)
Women	1650 (83.3)	78 (62.5)	19 (54.3)
Deg. Dif.			
Poorly	222 (11.2)	28 (23.3)	17 (48.6)
Moderate	102 (5.1)	22 (18.3)	3 (8.6)
Well	1661 (83.6)	70 (58.3)	15 (42.8)
N: 1	824 (41.5)	89 (74.2)	33 (94.3)
M: 1	27 (1.4)	7 (5.8)	10 (28.6)
Recurrency	197 (9.9)	49 (40.8)	25 (71.4)
5-year survival	1868 (94.1)	84 (70.0)	11 (31.4)

p-value for all cases was 0.01

In patients from groups T4a and T4b, the most frequently observed invasion of tumor upper

respiratory tract in 79 patients, and 17 patients with elements of the throat, as a rule in cricoid cartilage, in two cases small place subtotal affection of larynx. In 28 patients a small place of germination, as a rule, primary tumor, wall of the internal jugular vein, and in 5 cases from both sides of the neck. In 33 patients before the operation took place a paresis of the throat, due to invasion or compression of the recurrent nerves, during the operation, the germination of the nerve was observed in 16 patients, and two cases from both sides. In 20 patients were observed an invasion of the tumor in the esophagus was, in one case destruction of the neck department of the esophagus. In 5 cases of wall damage of the common carotid artery, 19 patients have a small place of tumor germination in the prespinal fascia. In 20 patients a small place local spread of the primary malignant tumor in the front-skin tissues of the neck and skin. There was no significant difference between the locales in groups T4a and T4b, but the T4b group had a lot more simultaneous invasive. In total, 27 patients were observed combined, double localization of invasive, and in 2 cases of 3 invasives at the same time. For comparison, data on the localization of primary tumor invasions are presented in Table 2.

Table 2) Localization of primary tumor invasions in absolute and percentage indicators

Invasive localization	Number	Percent
Upper respiratory tract	79	43.9
Hypodermic cellular tissue and skin	20	12.9
Esophagus	20	12.9
Recurrent nerve	16	10.3
Internal jugular vein	28	18.1
Prespinal fascia	19	12.3
Carotid	5	3.2

Depending on the degree of prevalence and invasion of the primary tumor, the results of treatment of patients, recurrence of disease in the group of non-invasive tumors T1-3 were observed in 9.9% of patients, while patients of T4a group were 40.8%, and in the group, T4b was the worst indicator of 71.4% of patients. Also, the ratio of 5-year survival was quite different, in the group of non-invasive tumors T1-3 it was the highest and made up 94.1%, and worsened depending on the degree of invasion, in group T4a was 70.0%, and T4b 31.4%.

The results of the treatment of patients in study groups which depended on the degree of differentiation of the tumor were analyzed. The percent ratio of patients in study groups, depending on morphological differentiation of tumors is given in Diagram 1 depending on prevalence and degree of initial tumor invasion statistically decreased morphological differentiation by groups, in the composition of noninvasive tumors of group T1-3, were found in 83.6% of patients with well differentiated tumors. While patients in the T4a group made up 58.3%, and in group T4b 42.9%. Poorly differentiated tumors in group T1-3 were in

Peculiarities of Clinical and Morphological Characteristics of ...

11.2% of patients, in group T4a 23.3%, and in group T4b this indicator was 48.6%. There was a clear correlation between reduced morphological differentiation depending on the spread and degree of invasion of the primary tumor (Diagram 1).

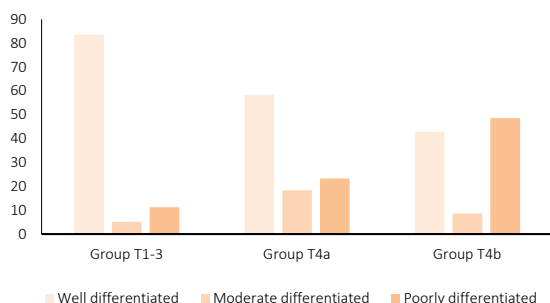


Diagram 1) Percentage of patients in study groups, depending on morphological differentiation of tumors

Results of complex treatment of patients in study groups depending on morphological differentiation of tumors, namely indices of recurrence and 5-year survival are given in Tables 3 and 4.

Table 3) Indicators of recurrence and 5-year survival depending on morphological differentiation of tumors

Differentiation	Groups (%)		
	T1-3	T4a	T4b
Recurrence			
Well-differentiated	6.4	27.1	42.9
Moderate differentiated	19.6	59.1	100.0
Poorly differentiated	31.5	64.3	82.4
5-year survival			
Well-differentiated	96.9	90.0	53.3
Moderate differentiated	85.3	45.5	0.0
Poorly differentiated	77.5	39.3	17.6

p-value for all cases was 0.01.

Analyzing the results of treatment of patients, the clear correlation of deterioration of indicators with reduction of morphological differentiation of tumors. It was also necessary to notice that at the onset of the recurrence of the disease, especially at moderate and poorly differentiated tumors, the prognosis for the life of the patient was considerably worse. In group T4a at the onset of recurrent disease of moderate and poorly differentiated tumors, 5 years lived only one patient, and in the group, T4b was marked by 100% mortality.

It should also be noted that during the radioiodine therapy in patients with relapse, or with palliative operations in a highly differentiated tumor, even taking into account large doses of pharma 131I, was marked very small or complete absence of its accumulation in the final or recurrent tumor, which means low efficiency of radioiodine therapy and high refractoriness, and high malignant potential of the advanced well-differentiated thyroid cancers. Moreover, the refractory to radioiodine therapy grew with the degree of prevalence and invasion of the primary tumor, in group T4a radiotherapy was little or ineffective in 7 out of 18 patients (38.9%),

and in group T4b in 7 out of 8 patients, which made up 87.5%. Therefore, despite the highly differentiated structure of papillary and follicular cancers of the thyroid gland, common cancers should be treated as tumors with high malignant potential, using the most radical operation.

It has been found that, depending on the prevalence and degree of invasion of tumors, the average age of patients has increased, the number of men in groups has increased, and the number of patients with regional and distant metastases has increased, which has worsened the prognosis of treatment of patients. All patients were screened for long-term permanent screening, to control recurrence or prolongation of the disease in patients with well-differentiated cancers, the level of stimulated thyroglobulin and its antibodies, as well as thyroid hormone and free thyroxine with diagnostic scanning 131I, in cases of medical calcitonin screening. All patients were screened by ultrasound and, if necessary, by computer tomography of soft tissues and organs of the neck and upper mediastinum for at least five years of observation.

Discussion

According to studies, the main factors that worsen the prognosis of treatment are tumor size, its spread on the surrounding thyroid gland of organs and tissues of the neck and mediastinum, and low morphological building tumor [9, 10]. Some authors offer several factors influencing the prognosis of treatment, it is as AMES (age, metastases, extent, size) or MACIS (metastases, age, completeness of excision, invasion, size) [11, 12]. But in our opinion, the most important prognostic factors in the case of advanced malignant tumors of the thyroid gland are histological differentiation and the prevalence of the invasion of tumors. In the world, according to the histological classification of malignant tumors of the thyroid gland, in the fallow period as a prognostic factor, more than two dozen types of carcinomas have been described, that is, epithelial tumors, and no less than rare types of malignant tumors from other tissue systems of the human body [13, 14]. But in our opinion, the most important stage of differentiation of tumors, and in our research group tumors are divided into well, moderate, and poorly differentiated, which is more than enough for the prognosis and choice treatment strategy of patients. Depending on the primary site, malignant tumors of the thyroid gland are most commonly spread in pre-thyroid muscles and soft tissues of the neck, recurrent nerve, internal jugular, rare in the upper respiratory tract (trachea, laryngeal elements), esophagus, organs of the mediastinum, carotid artery and pre-spinal fascia as a rule, with massive metastasis in regional lymphatic nodes [15, 16]. According to the latest AJCC classification of the 8th edition, the invasion of tumors in the soft subcutaneous tissue of the neck, laryngeal nerves,

internal jugular vein, upper respiratory tract, and esophagus belong to category T4a. The such tumor can be relatively radically operated at the first stage. But also the growth of tumors in the main arteries, middle and pre-spinal fascia eliminates the possibility of radical surgical intervention at the first stage and requires neoadjuvant methods of treatment, in particular antitumor chemotherapy, or palliative and symptomatic treatment, especially in cases of poorly differentiated forms of the disease, and also the invasion of tumors belong to category T4b [17-19].

Patients with locally-advanced malignant tumors of the thyroid gland, in a greater percentage of the level with patients with tumors of the initial stages, have a more elderly age, a lower morphological differentiation of tumors, and a greater number of associated diseases. On the one hand, only radical surgery in complex treatment gives a chance to recover the patient or can significantly improve the life expectancy of such complex patients. But on the other hand, it is necessary to take into account the large trauma of extended operations in elder patients with a large number of associated diseases, which can significantly reduce the quality of life of the patient [20-22]. It is also necessary to note that the untreated papillary or follicular cancers of the thyroid gland with massive contamination and metastasis, in half cases refractory to radiotherapy, this suggests a bad differentiation of tumors with a large malignant potential and poor prognosis of treatment of patients [23-25].

Conclusion

One can conclude that the use of the most radical, "aggressive" surgical interventions in complex treatment allows in cases of well-differentiated tumors to significantly improve survival rates and reduce recurrence. Also, the use of radical methods of surgery improved the efficiency of treatment of the moderately differentiated tumors of the thyroid gland. Not looking at the use of aggressive radical surgery in the complex treatment of patients, the worst indicators remain in cases of moderate and poorly differentiated forms of the disease, but significantly improved quality and life expectancy, which is also important in cases of low morphological structure.

Acknowledgments: There is nothing to declare.

Ethical Permissions: A study was approved by the National Ethics Commission of the Ministry of Health of Ukraine, December 10, 2021, No 1012-21.

Conflicts of Interests: There is nothing to declare.

Authors' Contributions: Illia Deineko is the only author of this study.

Funding/Support: There is nothing to declare.

References

- 1- Ilderbayeva G, Zhetpisbaev B, Ilderbayev O, Taldykbaev Zh, Bekeeva S. Metabolic processes of organism in remote period after the combined effects of radiation and emotional stress. *Georg Med News*. 2016;250:76-82.
- 2- Fedorenko ZP, Gulak LO, Mikhailovich YU. Cancer in Ukraine: 2018-2019. *Bull Natl Cancer Regist Ukr*. 2020;12:58-9.
- 3- Dmytriiev D, Dmytriiev K, Stoliarchuk O, Semenenko A. Multiple organ dysfunction syndrome: What do we know about pain management? A narrative review. *Anaesth Pain Intensive Care*. 2019;23(1):84-91.
- 4- Haugen BR, Alexander EK, Bible KC, Doherty GM, Mandel SJ, Nikiforov YE, et al. 2015 American Thyroid Association Management guidelines for adult patients with thyroid nodules and differentiated thyroid cancer: the American Thyroid Association guidelines task force on thyroid nodules and differentiated thyroid cancer. *Thyroid*. 2016;26(1):1-133.
- 5- Svyatova GS, Abil'Dinova GZh, Berezina GM. The frequency, dynamics, and structure of congenital malformations in populations under long-term exposure to ionizing radiation. *Genetika*. 2001;37(12):1696-704. [Russian]
- 6- Tusupkaliev BT, Zhumalina AK, Zhekeyeva BA, Baizhanova RM. The state of proinflammatory and anti-inflammatory cytokines in blood serum of infants with low birth weight in the presence of intrauterine infection. *Int J Pharm Technol*. 2016;8(2):13676-93.
- 7- Ahn HS, Kim HJ, Kim KH, Lee YS, Han SJ, Kim Y, et al. Thyroid cancer screening in South Korea increases detection of papillary cancers with no impact on other subtypes or thyroid cancer mortality. *Thyroid*. 2016;26(11):1535-40.
- 8- Sharma A, Jasim S, Reading CC, Ristow KM, Villasboas Bisneto JC, Habermann TM, et al. Clinical presentation and diagnostic challenges of thyroid lymphoma: a cohort study. *Thyroid*. 2016;26(8):1061-7.
- 9- Roka R. Surgical treatment of locally advanced thyroid cancer. *Innov Surg Sci*. 2020;5(1-2):27-34.
- 10- Gay S, Monti E, Trambaiolo Antonelli C, Mora M, Spina B, Ansaldo G, et al. Case report: lenvatinib in neoadjuvant setting in a patient affected by invasive poorly differentiated thyroid carcinoma. *Future Oncol*. 2019;15(24s):13-9.
- 11- Avenia N, Vannucci J, Monacelli M, Lucchini R, Polistena A, Santoprete S, et al. Thyroid cancer invading the airway: diagnosis and management. *Int J Surg*. 2016;28(1):S75-8.
- 12- Ríos A, Rodríguez JM, Ferri B, Matínez-Barba E, Febrero B, Parrilla P. Are prognostic scoring systems of value in patients with follicular thyroid carcinoma?. *Eur J Endocrinol*. 2013;169(6):821-7.
- 13- Lloyd RV, Osamura RY, Kloppel G, Rosai J, editors. WHO classification tumors of endocrine organs. Geneva: World Health Organization; 2017.
- 14- Polatova DSh, Islamov UF, Davletov RR, Savkin AV, Sharipov MM. Oncologic outcomes of pelvic bone sarcomas surgical. *Int J Health Sci*. 2021;5(3):252-9.
- 15- Lee GH, Kang JY. Surgical treatment in locally advanced thyroid cancer - trachea, larynx, esophagus invasion management. *Int J Thyroidol*. 2018;11(2):99-108.
- 16- Abboud B, Abou Zeid H, Rohbane R, Jabbour H, Baradhi A. Surgical management and prognosis of thyroid

carcinomas invading adjacent structures. Otorhinolaryngol Head Neck Sur. 2016;2.

17- Kim TH, Kim YN, Kim HI, Park SY, Choe JH, Kim JH, Kim JS, Oh YL, Hahn SY, Shin JH, Kim K, Jeong JG, Kim SW, Chung JH. Prognostic value of the eighth edition AJCC TNM classification for differentiated thyroid carcinoma. Oral Oncol. 2017;71:81-6.

18- Metere A, Aceti V, Giacomelli L. The surgical management of locally advanced well-differentiated thyroid carcinoma: changes over the years according to the AJCC 8th edition cancer staging manual. Thyroid Res. 2019;12:10.

19- Tussupkaliev B, Zhumalina A, Zhekeyeva B, Sergazina T. The content of some essential micronutrients in infants with low birth weight with intrauterine herpes infection. Georg Med News. 2016;253:67-72.

20- Tatenov AM, Tuleuhanov ST, Amanbayeva MB. Research of the mechanism of recognition of cancer cells by T-lymphocytes of immune system. Physics and chemistry of this mechanism. Res J Med Sci.

2015;9(4):237-9.

21- Banyra O, Sheremeta R, Shulyak A. Strangulation of the penis: two case reports. Cent Eur J Urol. 2013;66(2):242-5.

22- Fugazzola L, Elisei R, Fuhrer D, Jarzab B, Leboulleux S, Newbold K, et al. 2019 European Thyroid Association guidelines for the treatment and follow-up of advanced radioiodine-refractory thyroid cancer. Eur Thyroid J. 2019;8(5):227-45.

23- Li J, Yang GZ, Gao LX, Yan WX, Jin H, Li L. Hyalinizing trabecular tumor of the thyroid gland: case report and review of the literature. Exp Ther Med. 2012;3(6):1015-7.

24- Fujimoto N, Matsuu-Matsuyama M, Nakashima M. Single neonatal irradiation induces long-term gene expression changes in the thyroid gland, which may be involved in the tumorigenesis. Sci Rep. 2021;11(1):23620.

25- Studeny T, Kratzer W, Schmidberger J, Graeter T, Barth TFE, Hillenbrand A. Analysis of vascularization in thyroid gland nodes with superb microvascular imaging (SMI) and CD34 expression histology: a pilot study. BMC Med Imaging. 2021;21:159.